
2

Chapter Two

Neuropathy

Related to Diabetes

“There is horrible burning pain and numbness in my feet. Medicines are not helping me. I don’t want an ulcer or an amputation.”

The News

“Read all about it!, Read all about it! The latest news about Neuropathy!,” shouts the newspaper boy standing on the street corner. And the millions of people throughout the world with neuropathy stop and take a copy of the paper. There is no charge for this SPECIAL EDITION OF THE NEWS. It is given out as a public service announcement world wide:

“A. Lee Dellon, MD wrote in 1988* that there was a new “OPTIMISM” for those with neuropathy. The underlying medical problem, like DIABETES, makes the nerves in the arms and legs more likely to get compressed in the natural tunnels at the wrist and elbow, ankle and knee. Compressed nerves gives symptoms of numbness, weakness, and pain. Dr. Dellon developed operations to remove the pressure from these nerves NOW.

PAIN CAN BE RELIEVED! SENSATION RESTORED! ULCERS CAN BE PREVENTED! AMPUTATION CAN BE PREVENTED! BALANCE REGAINED! TODAY WE SHOULD THINK OF A ‘NEW-ROPATHY.’

“Doctor Dellon,” said Rosita, a 48 year old Hispanic woman from California, “why doesn’t everyone know yet that people like me can be helped?” She was consulting me in the Dellon Institute located in San Francisco.

“How have you been helped, Rosita,” I asked her.

“Doctor Dellon, just three months ago you operated on my right foot. When I came to see you I had horrible pain in both my feet, like I was walking on broken glass,” she paused, remembering her difficulty in describing her problem, “and yet, Dr. Dellon, it was so strange because my feet were without much feeling, almost like I was walking on a sponge or blocks of wood. My feet have been like that for two years. That is when my medical doctor told me for the first time that I had diabetes and that I had neuropathy,” replied Rosita.

“What did your medical doctor do to help you then Rosita?”

“Doctor Dellon, he made me so scarred! He told me all I could do was get my blood sugar under control with medication and diet, lose weight, and

*Dellon AL: Optimism in diabetic neuropathy. Ann Plast Surg 20:103-105, 1988.

he gave me medication usually used for depression and seizures to control my pain,” she paused again, remembering her frustration, “But Doctor Dellon, those medications made my head spin. Already I have lost my balance and I fallen.” She paused yet again, afraid to tell me the worst news, “Doctor Dellon, she said that I now have one out of six chances to get an ulcer, and then an amputation. I am supposed to look at my feet with a mirror. What I have, the medical doctor said, Neuropathy, is progressive and irreversible. There is no hope for me.”

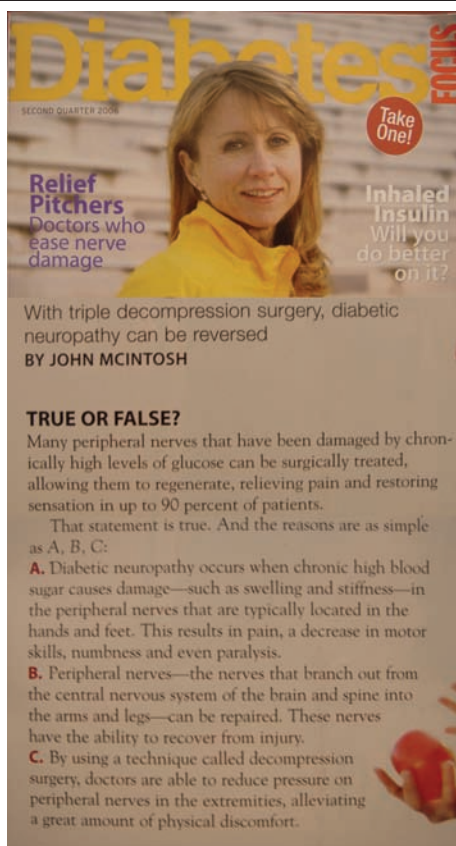


Figure 2-1. News from Diabetes Focus issue second quarter 2006. Article features a Plastic Surgeon from New Jersey, trained by Dr Dellon to do this Triple Nerve Decompression surgery to relieve the symptoms of nerve compression in patients with diabetic neuropathy. The News about the “New-Ropathy” is finally getting out!

“Rosita, I understand why your medical Doctor got you so scared,” I said. When I examined you, I found that you had nerve compressions at your knee, the top of your foot, and your ankle. “Now that you have had my operation, which, as you know, we call the “THE DELLON TRIPLE NERVE DECOMPRESSION,” how does your right leg feel, the one I operated on, compared to your left leg?”

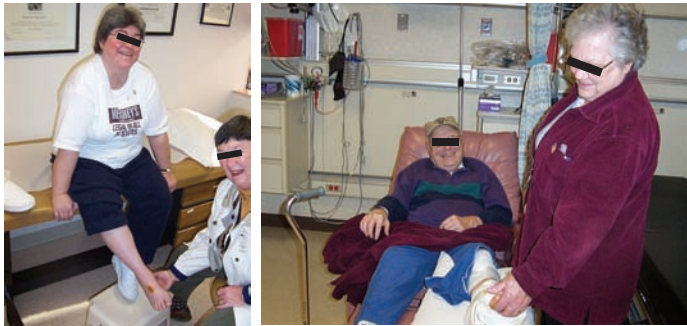

Figure 2-2. Two patients having their operated foot tickled. On the left, two weeks after having the Dellon Triple Nerve Decompression Procedure. On the right, in the recovery room. About half of the people who have this surgery appreciate increased sensation and relief of pain in the early post-surgery time period. Balance is restored when sensation returns. With return of sensation, the neuropathy progression stops. There are no ulcers or amputations.



Figure 2-3. Doctor Scott Nickerson, an Orthopedic Surgeon, himself a diabetic, had the Dellon Triple Nerve Decompression procedure on both of his feet by Dr. Dellon. Dr. Nickerson has been greatly improved and now lectures to get the “News,” the Optimism about neuropathy, out to the public in his own state of Wyoming, and to the diabetic community at large. A foot being tested painlessly with the Pressure-Specified Sensory Device™ (PSSD), is shown on his computer screen in the background.

“Doctor Dellon, now at 3 months since your surgery, the pain is almost gone in my right foot, and I can feel it when you touch the bottom of my right foot. My left leg, without surgery, still feels the same. Doctor Dellon, how soon can you do the surgery on my other foot? Then I can stop taking all these pain medications. Doctor Dellon, you have given me hope.”

And from across the USA, the “News” is making headlines.

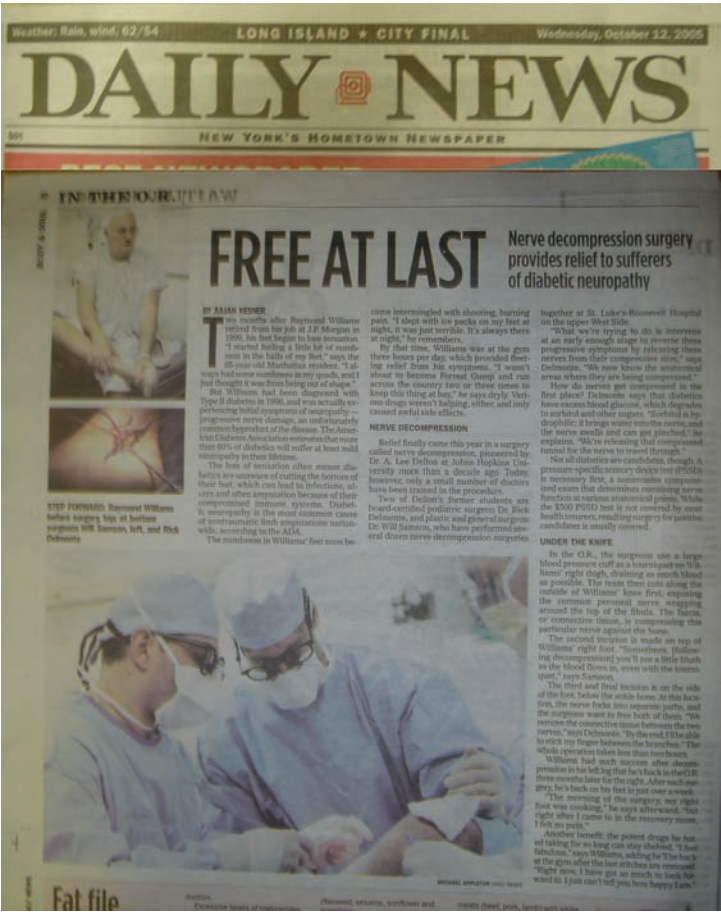

Figure 2-4. Two surgeons in New York City, trained by Dr. Dellon were in the News for their work with the Dellon Triple Nerve Decompression surgery. The “News” continues to be told that this surgery can relieve pain and restore sensation for patients with neuropathy who also have nerve compression(s) in their legs. This surgery is not for everyone with neuropathy, but for that subgroup that also has nerve compressions.

The Old Neuropathy

If you are reading this you most likely have a form of neuropathy.

There are many kinds, but the most common in the world is due to diabetes. Diabetes costs the health care system in the United States one out of every seven dollars. A large part of this cost goes to paying for pain medication for neuropathy, paying for the cost of healing an ulcer (about \$28,000), paying for an amputation (about \$40,000), paying for hospitalization for a foot infection (about \$100,000), or paying for the cost of a broken hip or wrist (due to a fall from loss of balance).

Half of people with diabetes will get neuropathy after having diabetes for about ten years. Ten percent of people first learn they have diabetes when they see their doctor because of their foot pain. One of six diabetics with neuropathy will develop and ulcer. One of six of these people will have an amputation. Half of those with an amputation on one side will get an amputation on the other side, and then half of these people will be dead in three years.

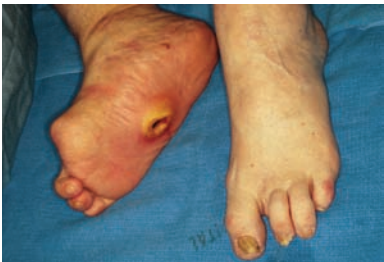

Figure 2-5. The expected results of neuropathy: **ulceration, infection, amputation.**




Figure 2-6. Recent News article describing impact of cost of treatment of the complications of Diabetic Neuropathy in the United States. These costs can be reduced greatly by the Dellon Triple Nerve Decompression surgical procedure.

The “Old” Versus “New” Neuropathy Approach

OLD VERSION: NEUROPATHY IS PROGRESSIVE AND IRREVERSIBLE.

With the *old* or traditional approach to neuropathy, the concept was for the medical doctor to treat any underlying known medical cause for the basic disease, like diabetes, and, then to give the patient medication for pain, if pain were part of the neuropathy. As the sensibility became lost, all that could be done was instruction in care for the insensitive foot (using a mirror to look at the bottom of your feet everyday) and wearing special, protective shoes. The neuropathy could be predicted to progress, meaning to get worse, leading to ulceration, infection, amputation, and falls due to loss of balance. In the traditional approach, the doctor did NOT examine the patient for the presence of nerve compressions in the leg or foot. These are NOT present in all patients with neuropathy. Those with and without nerve compressions were thought to be the same and have the same cause for their symptoms.

With the *new* or *Dellon Institute approach to neuropathy*, the concept is that the underlying medical problem makes the peripheral nerves susceptible to compression. This compression may be the primary source of the symptoms. Even if we do not know the cause of the neuropathy,* there is hope for relief of symptoms, because a compressed nerve can be approached with surgery. The site at which the nerve is compressed, or pinched, can be opened.

*Idiopathic neuropathy means an unknown cause for the neuropathy.

Decompressing the nerve can relieve symptoms, relieving pain, and restoring sensation. If there is recovery of sensation in the foot, there will not be an ulceration, an infection, or an amputation. See Figure 2-7 and 2-8 for proof of this statement.

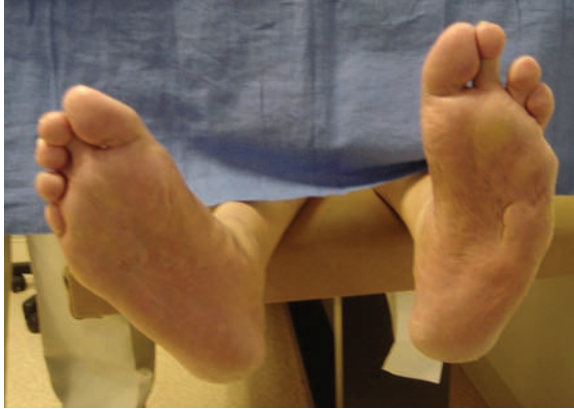

Figure 2-7. **Proof that nerve decompression can prevent ulceration and amputation.** The right foot had the Dellon Triple Nerve Decompression 15 years ago. The left foot did not have the Dellon approach. The left foot has had the traditional expected result; progressive neuropathy with ulceration and amputation, in this patient, of the fifth toe. In contrast, the right side has maintained sufficient sensation that there has not been ulceration or loss of tissue.

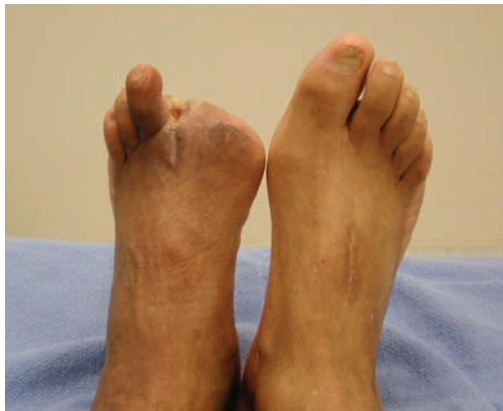

Figure 2-8. **Proof that nerve decompression can prevent ulceration and amputation:** Right foot had a Dellon Triple Nerve Decompression 7 years ago. Sensation recovered preventing ulceration and amputation. Left foot, without the Dellon Triple Nerve Decompression has developed ulcers, bone infection, and required 2 toe amputations.

Neuropathy can also cause motor weakness and paralysis.

In the “New-Ropathy,” the Dellon approach, nerve decompression surgery can also restore muscle function if the muscle has not completely atrophied (died). **One of the first muscle functions to be lost, related to the common peroneal nerve next to the knee, is lifting up the big toe (Figure 2-9), and then in time a “foot drop” develops. When this occurs, you may feel like you are stubbing your toe a lot, or dragging your foot, or feel as if your leg is going to give out.** In some patients, for reasons that are not understood, once this muscle imbalance occurs, the leg may seem “restless.” Once the muscle no longer has a nerve input to it, the muscle begins to atrophy, and then decompression of the nerve may no longer be effective.

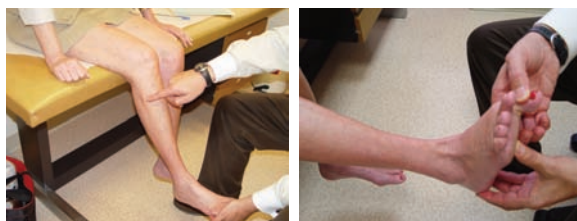

Figure 2-9. Left: Dr. Dellon's finger points to the site of nerve compression near the knee. This is the common peroneal nerve. This nerve provides sensation to the top of the foot and motor function that permits the toes and ankle to lift up. Note area of indentation of the muscle near the finger related to muscle wasting. Right: Dr. Dellon demonstrates weakness in the long toe extensor, the first muscle to become weak with nerve compression. Decompression of the common peroneal nerve at the knee can reverse this weakness and restore strength if the muscle has not become atrophied.

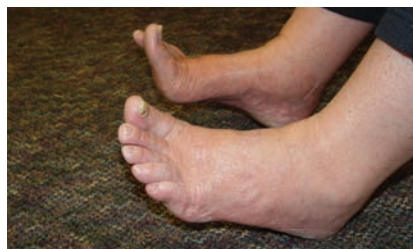

Figure 2-10. The left foot has NOT had surgery. The left big toe is partly paralyzed and does not lift up (extend) completely. Both feet had the same degree of motor weakness and paralysis. The right leg in this photo is three months after a Dellon Triple Nerve Decompression surgery. **Note the right big toe can completely extend now after surgery.**

When the small muscles in the foot become weak or paralyzed, a “claw foot” develops, as in Figure 2-11 and 2-12. **If motor function improves after the nerve decompression surgery, then the paralysis can sometimes be reversed.** Figure 2-10 and 2-12 are proof of this statement:

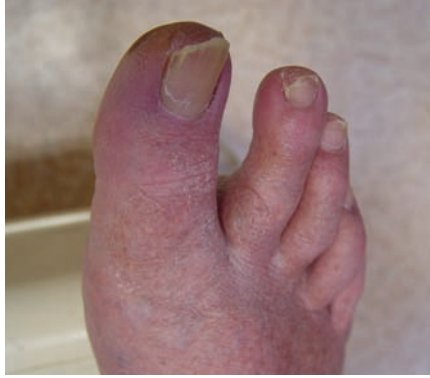

Figure 2-11. The foot of a man with advanced diabetes demonstrates clawing of all toes except the big toe. These toes are hyperextended (bent back towards the foot) because the small muscles that bend the toes are weak or paralyzed. Note skin dryness due to sympathetic (sweating) nerve failure too.

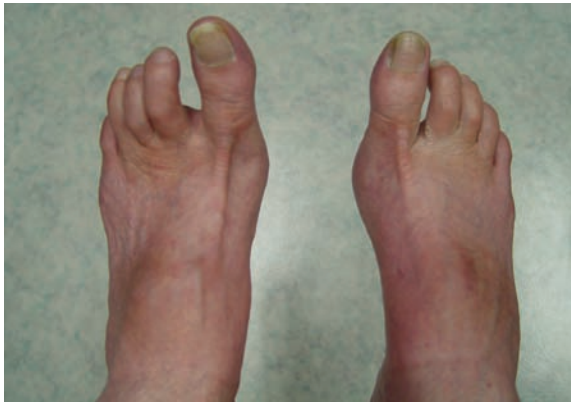

Figure 2-12. Claw & Reversal. The left foot has NOT had surgery. Note that all toes except the big toe are curved back towards the foot, while the tips bend forward, creating a “claw foot” deformity. Six months ago, both feet looked exactly the same. The right foot had a Dellon Triple Nerve Decompression 6 months ago. **As strength comes back into the small muscles on the bottom of the foot, innervated by the tibial nerve in the tarsal tunnel, the small toes can regain the strength to flex, removing the claw deformity from the foot.**

Restore the Balance to Your Life



Figure 2-13. Balance has been restored to each of these two patients with neuropathy. Top: This 72 year old woman was no longer able to enjoy even just simply walking her dog in the woods behind her house. Here she is shown doing exactly that after having a Dellon Triple Nerve Decompression Surgery on each foot. Bottom: A 27 year old Type I diabetic with severe neuropathy, has regained her balance sufficiently after her Dellon Triple in each leg so that she can resume her favorite activity, water skiing, again.

Get Yourself “New Balance”

Historically, when you lost sensation in your feet, you would lose balance causing falls (Figure 2-9), and perhaps a broken wrist or hip. [With the Dellon approach, if you can get your sensation back, your balance can return too.](#) This is demonstrated by the following illustrations in [Figures 2-14A and 2-14B.](#)

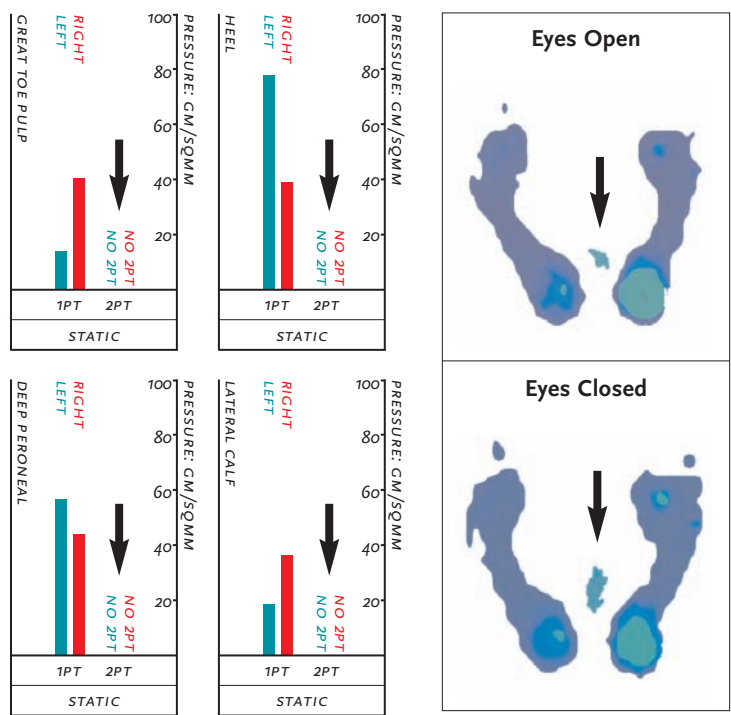


Figure 2-14A. On the left is the computer print out from the Pressure-Specified Sensory Device™ (PSSD) which has documented absence of ability to distinguish one from two touch points (arrows) at four areas of the foot, with the same severe loss of nerves being present both on the left (blue bars) and the right (red bars), which is the picture of an advanced neuropathy. Without sensation, the brain cannot tell in what position to hold the body. On the right, the foot prints obtained from a computer on which the patient is standing, shows the grey area of the center of gravity and how it changes position over 30 seconds. In the top on the right, the patient’s eyes are open, and vision is used to maintain the balance. In the bottom on the right, with the eyes closed, the brain must depend on sensory input from the feet, which, as is shown on the left is very poor. Accordingly, the grey outline of the center of gravity increases. This change in center of gravity area is called “sway” and is a measure of loss of balance. This patient, without much sensation due to advanced neuropathy, has increased sway, or decreased balance.

The patient in Figure 2-14A has loss of balance due to loss of sensation. This person cannot stand at night without touching the wall of the bedroom, unless the lights are on. The feet cannot send enough sensory information to the brain. This person falls regularly.

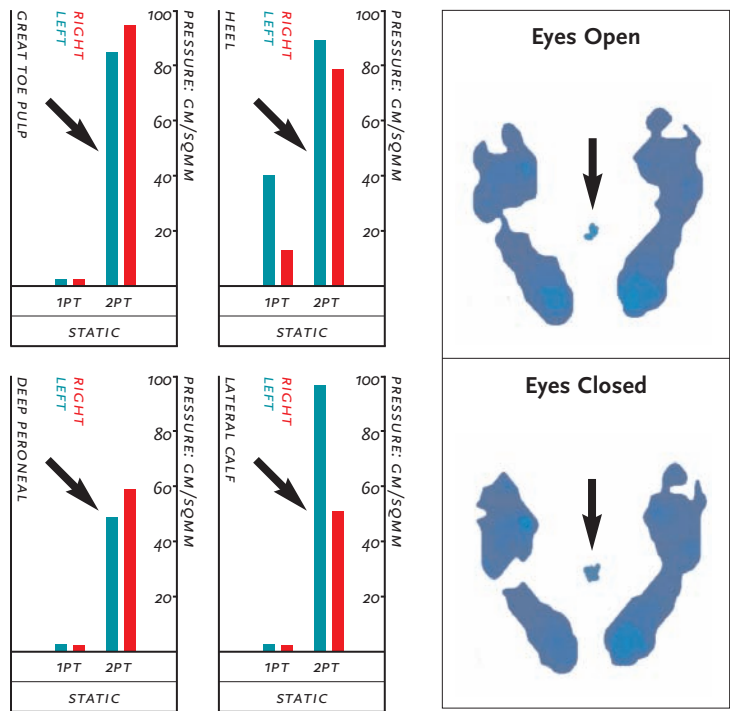


Figure 2-14B. The same measurements as in 2-14A, on the same patient. The right foot is 6 months after a Dellon Triple Nerve Decompression, and the left leg is three months after the same operation. On the left side of the figure, note that the blue and red bars (arrows) on the graph that were absent in Figure 2-14A are now present. This demonstrates that sensation has recovered in the top and bottom of both feet. While the sensation is not yet normal, sensation is greatly improved from before surgery. On the right side of Figure 2-14B, note that the grey area representing the center of gravity, is now about the same with the eyes open and with the eyes closed. Sway is the same with the eyes open or with the eyes closed which is very different than before surgery. Balance is now restored. This means that enough information comes to the brain through the feet that balance is maintained. This patient will no longer fall. In addition to demonstrating that the Dellon Triple Nerve Decompression surgery restores balance, Figures 2-14A and B demonstrate how the Pressure-Specified Sensory Device™ can document the present and stage of neuropathy and also document nerve regeneration during recovery from the surgery.

The Insight

“Doctor Dellon, you have helped my hands, can you help my feet?”

As a Plastic Surgeon who was also a Hand Surgeon, I often would operate on the hands of patients who had nerve problems due to diabetes. About one out of 5 diabetics will develop numbness in the thumb, index and middle finger, that awakens them from sleep. This is called *carpal tunnel syndrome*. These symptoms are due to compression of a nerve the size of a pencil in a tight tunnel in the front of the wrist. The pressure on the nerve causes blood flow to slow down, and when the nerve does not get enough oxygen, the nerve responds by sending a message of numbness or tingling to the brain. Although the existence of this carpal tunnel problem was known in the late 1800’s, the first operation to relieve this pressure was probably not done until about 1940, and the surgical release of the ligament across the carpal tunnel to treat carpal tunnel syndrome was not widely accept until the 1950’s. Carpal tunnel decompression surgery should give relief of symptoms in 90% of patients. [I would do this surgery for my diabetic patients with carpal tunnel syndrome, and they would ask me,](#)

[“Doctor Dellon, you have helped my hands, can you help my feet?”](#)

“What is wrong with your feet?” I would answer, because our Plastic Surgery and Hand Surgery training did not teach us much about foot

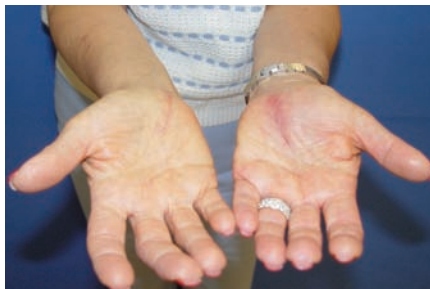

Figure 2-15. “Doctor Dellon, you helped my hands, can you help my feet?” The scars can be seen in the palm of the hands of this woman with neuropathy in her feet and also had carpal tunnel syndrome in each hand. The right hand had decompression of one nerve, the median nerve in the carpal tunnel 6 months before, and left hand had the same surgery 2 months before this photo was taken. The numbness and tingling in her hands are gone. They do not bother her at night. She wanted me to do a nerve decompression on her feet, to give them relief too. [Is there a carpal tunnel in the foot?](#)

problems in patients with diabetes. I knew neuropathy existed and led to ulcers, infections and amputations. I knew in neuropathy, sensation was lost in the pattern of glove in the hands and arms, and in the pattern of a stocking in the legs and feet. The problems in the feet usually began first. But the symptoms of carpal tunnel syndrome were in the pattern of just one nerve, the median nerve, while the neuropathy was not the pattern of one nerve.

“Doctor Dellon, my toes feel like my fingers did, but my toes are more numb, and they hurt. The numbness and pain began in my feet and is moving up my leg. Can you help me?” my hand surgery patients would ask?

There were patients with diabetes who had numbness in their little and ring fingers, and clumsiness in their hands. They dropped things. Their hands become weak. The back of their little and ring fingers became numb also. They had ulnar nerve compression at the elbow. This is called *cubital tunnel syndrome*. This problem was known in the late 1800’s, but successful surgery to help this problem was not done till about the 1940’s, similar to the story of carpal tunnel syndrome. So, I would decompress the ulnar nerve at the elbow, and the patients would say,

“Doctor Dellon, you helped my hands, can you help my feet?”

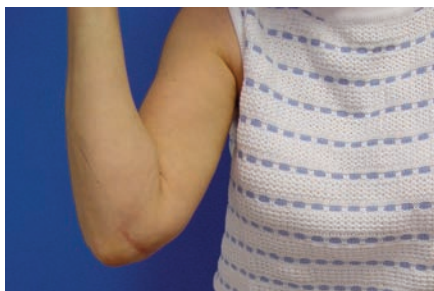

Figure 2-16. The scar at the inside of the elbow is the location for my operation to decompress the ulnar nerve at the elbow in the cubital tunnel. Symptoms from this site of location are numbness in the little and ring finger and part of the back of the hand, and weakness and clumsiness using the hand. This woman, who has neuropathy in her feet, also had cubital tunnel syndrome. Here she is 3 months after ulnar nerve decompression and her symptoms are gone. She wants me to operate to relieve the symptoms in her feet. [Is there a cubital tunnel in the leg?](#)

There were patients with diabetes who had numbness and burning over the back of their thumb, index finger and back of their hand. In 1932 there was a report of a diabetic who had these symptoms, but it was thought to be an inflammation of the nerve. In 1986, a site of nerve compression was described by myself and a co-worker.* This site of compression was in the forearm. The compressed nerve is the radial sensory nerve. When this nerve was decompressed, the numbness and burning would go away. “[Doctor Dellon, you helped the burning over the back of my forearm and hand, can you help the pain from my knee to the the top of my foot?](#)” asked a diabetic with neuropathy one day after I had helped her arm.

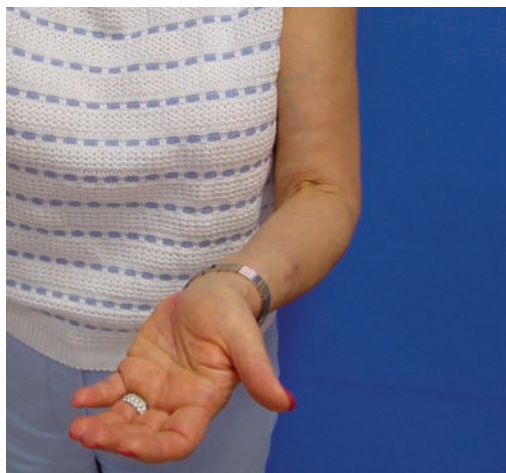

Figure 2-17. Note the small scar just above the bracelet on the left forearm. This is the site of compression of the radial sensory nerve. This woman now has relief of numbness and pain in the back of her forearm, wrist and hand. She had diabetic neuropathy. She wants me to do a similar operation on her leg to help the burning from the knee to the top of the foot. Is there a similar nerve compression in the leg that would make the top of the foot and ankle numb and burn?

*Dellon AL, Mackinnon SE: Radial sensory nerve entrapment in the forearm. J Hand Surg 11A:199-205, 1986.

“Doctor Dellon, you helped my hands, can you help my feet?” This question used to haunt me. Maybe the same type of nerve compressions did occur in the feet, and if they did, maybe the symptoms in the feet of people with neuropathy could be helped by decompressing these nerves. I began to work on identifying an approach to help these feet symptoms:

In the hand, I could decompress three nerves, a *Triple Nerve Decompression*, to give relief in the pattern of a glove. In the leg, could a Triple Nerve Decompression give relief in the pattern of a stocking?

Three nerves sites of compression can give the pattern of a stocking.



Figure 2-18. If you combine the patterns of the skin affected by compression of the three nerves in the hand and arm, the median nerve in the carpal tunnel, the ulnar nerve in the cubital tunnel, and the radial sensory nerve in the forearm, you get the total sensory area of a glove. What nerve skin patterns would be necessary to give you a stocking? The nerve near the knee, the common peroneal nerve, and tibial nerve, on the inside of the ankle, would give you that pattern. The common peroneal nerve has an entrapment site for one of its branches also in the lower leg and the also on the top of the foot. The tibial nerve has a known description for compression in the tarsal tunnel. Would the same approach I had taken in the hand work in the foot? This was what I had to find out!

The Dellon Triple Nerve Decompression

In 1980, the first patient with a tarsal tunnel syndrome was referred to me. It was first thought by his doctors that his numbness and burning in his feet was due to a circulation problem. Jacob was 73 years old.

“Doctor Dellon,” Jacob informed me, “I have retired from many years of public service in our government, and have lived an active life. My health has been great. As I have gotten older, I remember my parents needing to put a blanket around their legs as they got older. They would tell me their feet felt cold, and bothered them at night. They had problems with their balance too. Unfortunately, this has been happening to me for several years now. I thought that maybe modern medicine has found relief for this problem. But the vascular surgeons told me my circulation was great for someone my age, and that maybe you could find a nerve compression in my feet that is giving me these symptoms. The Chief of Vascular Surgery at Johns Hopkins Hospital, Dr. Melville William, I said I had ‘tarsal tunnel syndrome’, and that maybe you could help me.”

“Yes, Jacob, I will try to help you. But you have a rare problem, and in truth, I have never operated on this problem before, so let me do a little reading* and research into Tarsal Tunnel Syndrome. Come back in a few weeks and we can make a plan together,” I replied.

Jacob came back to see me. “Jacob,” I said, “when a person has symptoms related to carpal tunnel syndrome, there is usually a place where the doctor can tap over the nerve, and if the nerve is compressed, the patient feels a tingling sensation go out into the fingers. This is called a ‘positive Tinel sign, after a French doctor. It was also described by a German doctor, Doctor Hoffman. They both identified this sign working with injured soldiers from World War I, and described this sign in 1918. Let me see what happens when I tap on the tibial nerve in the tarsal tunnel region of your ankle.”

“Doctor Dellon, when you tap there, I do get a sensation into the bottom of my foot and it goes out towards my toes,” replied Jacob after I tapped on his ankle.

The Tarsal-Tunnel Syndrome

BY CAPTAIN CHARLES KECK, *Medical Corps, United States Army*

From the United States Army Hospital, Fort Hood, Texas

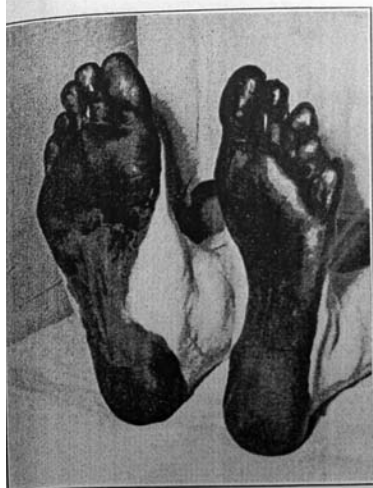


FIG. 1-A

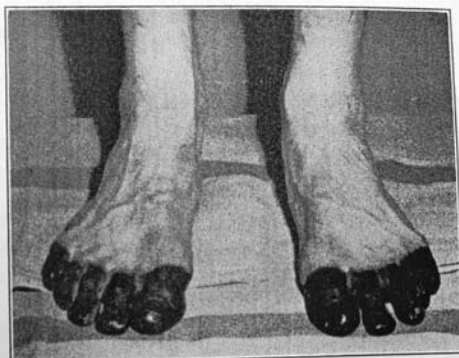
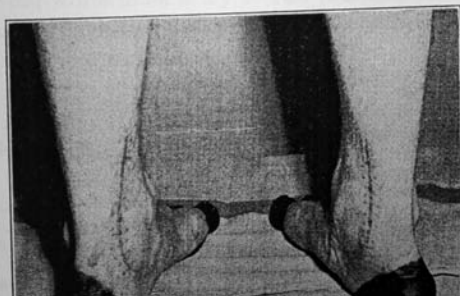


FIG. 1-B



Figs. 1-A, 1-B, and 1-C: The distribution of complete anesthesia is indicated in black. Note in Fig. 1-C the extent of the operative incision for decompression of the posterior tibial nerve in the tarsal tunnel.

Figure 2-19. Photos of one of the first patients described with numbness and tingling in the darkly colored portions of the feet. This is one of the first papers to describe tarsal tunnel syndrome, which Doctor Keck, the author of the paper* described as being the carpal tunnel syndrome of the foot. The length of the incisions for the decompression surgery is seen in the lower right. Note they come quite high on the leg and not too far past the ankle. It was recommended that the foot be immobilized for 3 weeks to permit healing. The patient should not walk on the foot during that time, but use crutches. (With permission of the publisher.)

*Keck, C., Tarsal-Tunnel Syndrome, *J. of Bone and Joint Surgery*, 44A: 180-182, 1962.

“Jacob, this is very good news! I have been studying this problem. In the hand, there is just one tunnel that compresses the median nerve in the carpal tunnel. The location of the surgery described for tarsal tunnel surgery does not correspond with the location of the carpal tunnel in the hand. In fact, the tarsal location in the foot is actually the area of the wrist, the end of the forearm. I have identified the exact location for the compression of the nerves that go to the foot and toes and small muscles of the foot. There are actually four separate tunnels to release. I have designed an operation that combines two of these tunnels into one larger one, and I believe that this will relieve your foot symptoms from compression on the nerves.”

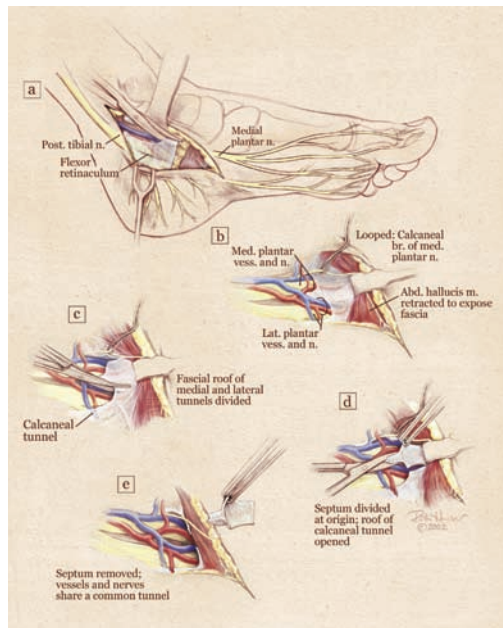


Figure 2-20. Dellon approach to the tarsal tunnel decompression. Four medial ankle tunnels are decompressed instead of just the one tarsal tunnel. In A) the white tissue is the covering of the tarsal tunnel. This is release to identify the important nerve patterns and the blood vessels within the tarsal tunnel itself, even though this large tunnel is usually NOT the site of pressure. In B), one of the foot muscles is retracted to show the roof of the tunnels with the most pressure upon the nerves, the medial and lateral plantar tunnels. In c and d) each of these tunnels is released, and in d) the tunnel to the nerve to the heel, the calcaneal nerve is also released. In e) the divider of the two tunnels is removed to create one large space for the nerves to travel in, completing the decompression. (With permission <http://www.dellon.com>)

My operation on Jacob for his tarsal tunnel syndrome began an enduring fascination with the nerve problems in the lower extremity. Today my approach to decompressing the four medial ankle tunnels is becoming the standard for treating this problem. As my new brochure, *Tarsal Tunnels Syndrome* (go to Dellon.com, and click on BROCHURES in the banner at the top of the page), makes clear even by its very name, **it is critical to decompress each of these four tunnels to get relief of the foot and toe symptoms related to tibial nerve compression.**

My approach to the other major nerve pathway in the leg, the peroneal nerve, has incorporated several important concepts. First, for the site of

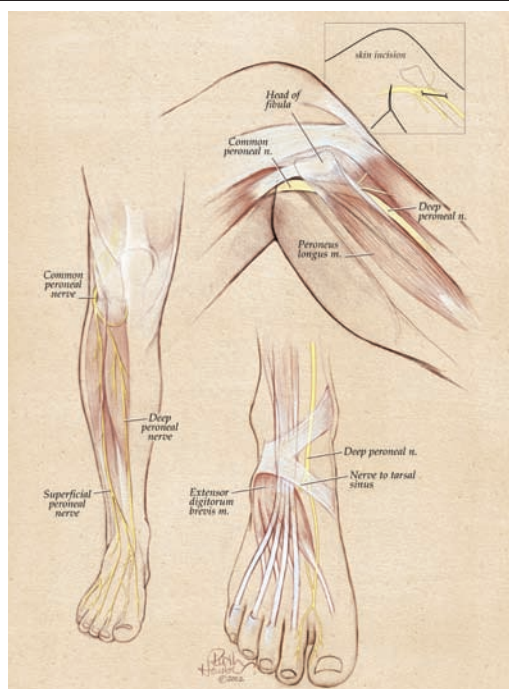


Figure 2-21. Sites for compression of the peroneal nerve branches in the knee, leg and foot. Incision to decompress the common peroneal nerve at the knee is shown in the upper right. The white covering of the muscles crossing this nerve cause compression of the nerve against the underlying the bone, the fibula. The deep peroneal nerve, in the lower right of this figure, is compressed against the underlying toe bones by an extra tendon. This tendon is removed. It is less common for the superficial peroneal nerve to become compressed on the outside of the leg, but this nerve, too, can be decompressed. (with permission <http://www.Dellon.com>)

compression at the knee, not only is the commonly opened connective tissue covering of the muscle that crosses the nerve released, but also, fibrous bands deep to that muscle, and fibrous bands deep to the nerve. This nerve at the knee is called the common peroneal nerve because it splits into one closer to the skin the lower part of the leg, the superficial peroneal nerve, and one beneath the muscles of the leg until it exits at the ankle, the deep peroneal nerve. In 1990, I described a site of compression for the deep peroneal nerve over the top of the foot.* This is a common site for nerve compression in patients with neuropathy, as is the site at the knee. Recently, the site of compression of the superficial peroneal nerve has been emphasized too. This less common site must be evaluated during the examination of the leg.

“Doctor Dellon, you helped my hands, can you help my feet?”

I used to say, “You had a nerve compression in your hands, but you have neuropathy in your feet, and a surgeon cannot operate on neuropathy.” Now I say, “Let me examine your feet. If I find evidence of nerve entrapment at known sites of narrowing, then you also have nerve compressions here just as you did in your hands. When these nerve entrapments are in the legs, it gives you symptoms similar if not the same as neuropathy. If you have the most common three areas for nerve entrapments in your legs, at the outside of the knee, at the top of the foot, and on the inside of the ankle, then a Dellon Triple Nerve Decompression surgery has an excellent chance of helping your feet.”

“Wonderful news Doctor Dellon. There is hope for me. But I am still a little confused. I am a diabetic. Will I still have neuropathy?”

*Dellon AL: Entrapment of the deep peroneal nerve on the dorsum of the foot. *Foot and Ankle* 11:73-80, 1990.

“Yes,” I reply, “and that is a confusing problem. The metabolic problems created by diabetes do keep the nerve from working properly, but I have found that without the sites of anatomic narrowing compressing the nerves, that is, when surgery relieves the pressure on the nerves, even though the nerve still has the diabetic metabolic abnormalities within it, you will have your symptoms relieved. This is because for many people, the symptoms are due to compression of the nerves.”

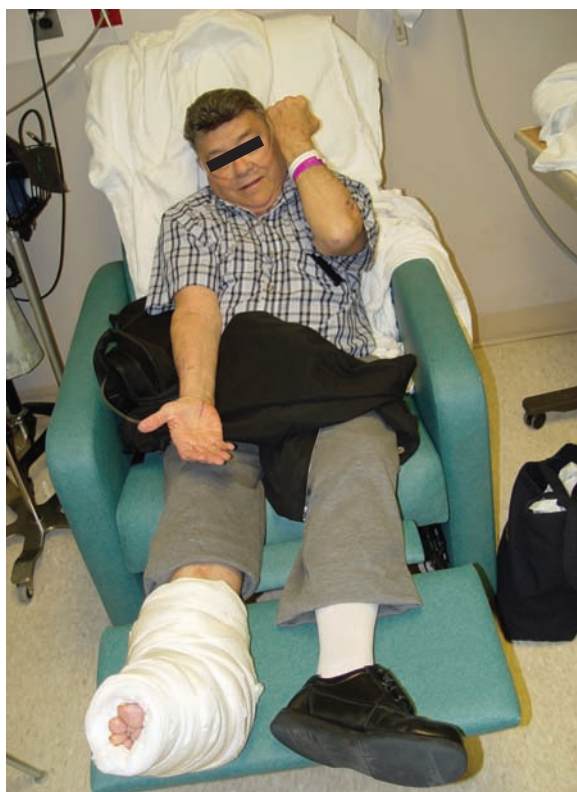

Figure 2-22. This man shows his wrist, forearm and elbow to demonstrate that he has already had relief of symptoms of nerve compressions in both of his arms. Some of the incisions have been outlined with a pen for visibility. He is diabetic with neuropathy. He is shown here with the bandage on his foot in the recovery room following a Dellon Triple Nerve Decompression to treat multiple nerve compressions in his right leg. The large dressing is placed to help him walk immediately after surgery using a walker. This allows the nerve to glide so they do not become entrapped again.

“Doctor Dellon, you helped my hands, and now you have also helped my feet. Thank you very much.” People who have all 4 extremities decompressed for symptoms of nerve entrapments I like to call “QUADS.”

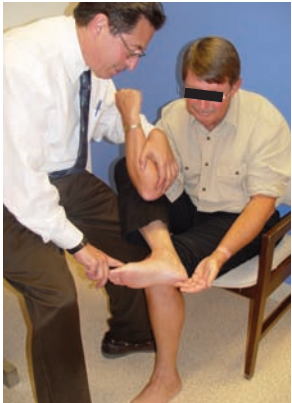

Figure 2-23. Doctor Dellon examines one of his first “Quads” who volunteers now to answer the Dellon Institutes “Diabetes Hotline” and its email “Pain Help Hotline” He is now eight years since his nerve decompressions in the year 1998.

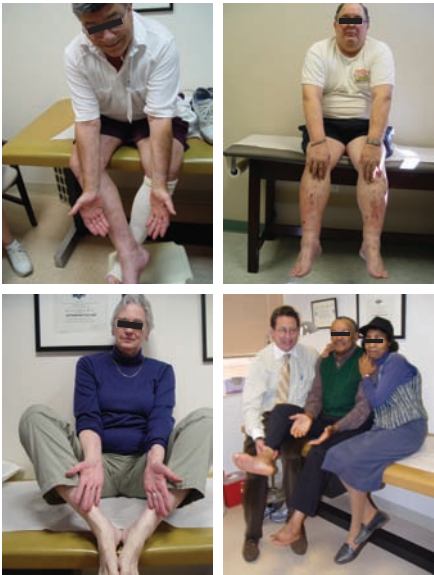

Figure 2-24. Four more patients who had a Dellon Triple Nerve Decompression in each of their four extremities, making them each a “Quad.” The concepts that work for nerve compressions in the arm and hand work also in the leg and foot.

“How Long will it Take, and How Long will it Last?”

These are natural questions to ask:

“Doctor, Dellon, if I have the Triple Nerve Decompression surgery, how long will it take for me to know if the surgery really worked, and how will the results last?”

Usually when I am asked, “How long will it take?” I often reply, “Do you want me to rush?”

Usually when I am asked, “How long will it take to recover from surgery?” I often answer, “I rest about 10 or 15 minutes and then begin another operation.”

Believe it or not, the patient usually laughs and relaxes a little bit.

The most common questions asked by patients with neuropathy are:

Q1) “Am I a good candidate for this surgery?” which I translate as asking “What are my chances for success?” and

Q2) “How long will it take for me to recover from my surgery?” which I translate as asking “When will my pain be gone and when will I get feeling back into my feet?” and

Q3) “How long will the results of the surgery last?” which I translate as asking “If I get good results, will my pain and numbness come back again?”

Let us give the answers by the numbers above:

ANSWER 1) CHANCE OF SUCCESS?

When I evaluate a patient with neuropathy, I am trying to decide if there is a place where a nerve is compressed. I tap along the nerve at the sites where compression can occur, demonstrated in Figure 9-25. When I tap on this site, if there is either pain or tingling going into the area of the symptoms, this is interpreted as being a “positive Tinel sign.”

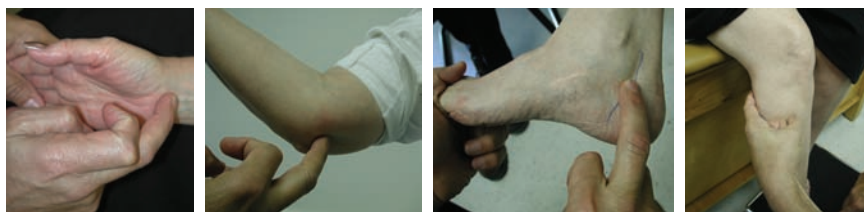

Figure 2-25. Examples of how I test for a local site of nerve compression in the patient with neuropathy. This is called the Tinel-Hoffman sign or simply, a positive Tinel sign.

If there is a positive Tinel sign, then your chance of having success with nerve decompression surgery, which is relief of symptoms, is at least 80%.*

ANSWER 2) HOW LONG TILL I KNOW IF THE SURGERY IS WORKING?

Each patient with neuropathy is tested with the Pressure-Specified Sensory Device™ (pssd).

This measures sensibility in the skin and relates to your symptoms. Traditional, usually painful electrodiagnostic testing does not correlate well with symptoms. A brochure about “pssd” testing is available on our website at DellonInstitutes.com. In 1989, I invented this computer-assisted neurosensory testing device with an aerospace engineer to help measure peripheral nerve function in the presence of neuropathy. The pssd gives better information than those little nylon filaments, called Semmes-Weinstein monofilaments, and

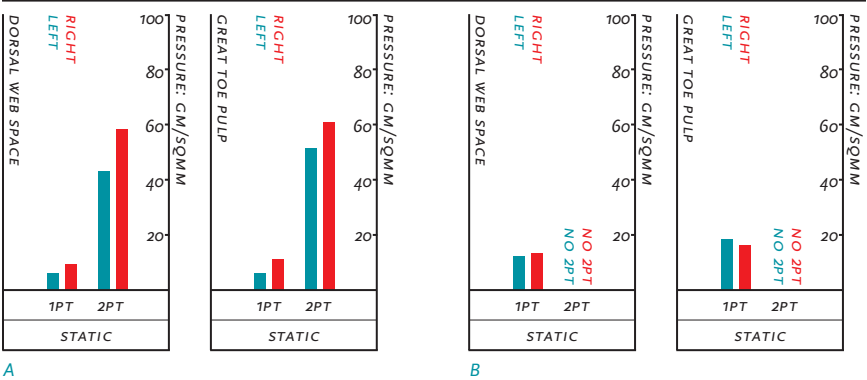


Figure 2-26. Neurosensory testing with the Pressure-Specified Sensory Device™ is demonstrated for a patient with neuropathy. The red color is the right and blue color is the left side of the body. The dorsal web is the top of the foot (peroneal nerve) and the great toe pulp is the big toe (tibial nerve). Higher numbers require more pressure and indicate a worse degree of nerve problems. When the red and blue bars are abnormal for both the peroneal (top of the foot) and the tibial nerve (the bottom of the foot), then the pssd test results documents neuropathy as it does in both A and B. In A), the patient can still distinguish one from two static points, although not at normal levels of pressure and distance. With this degree of nerve damage, and the presence of a positive Tinel sign, the patient can expect to recover sensibility by 3 months after surgery. In B), with complete loss of two-point discrimination, more nerve fibers have died, and recovery from the Dellon Triple Nerve Decompression procedures may take up to one year to recover.

*Lee C, Dellon AL: Prognostic ability of Tinel sign in determining outcome for decompression surgery decompression surgery in diabetic and non-diabetic neuropathy, Annals of Plastic Surgery, 53:523-27, 2004

better information than measurements with vibration** in predicting who will develop an ulceration. These measurements, illustrated in Figure 2-26, document that neuropathy is present, and measure the degree of nerve damage present. If you have a moderately severe degree of nerve damage (Figure 2-26A) you should know that you are recovering from the Dellon Triple Nerve Decompression by 3 months after surgery. If the damage is more severe (Figure 2-26B) you have lost more nerve fibers: recovery can take up to one year.

ANSWER 3) HOW LONG WILL THE GOOD RESULTS FROM SURGERY LAST?

My first surgical procedures to restore sensation and relieve pain in diabetics with neuropathy and nerve compression began in 1982, and I have been able to keep in contact with some of my patients for a very long time. For example Figure 2-7 shows the foot of a patient that had the Dellon Triple Nerve Decompression 15 years earlier, with enough sensation preserved to prevent ulceration and amputation in the operated leg. Another long-term follow-up example is given in Figure 2-27.

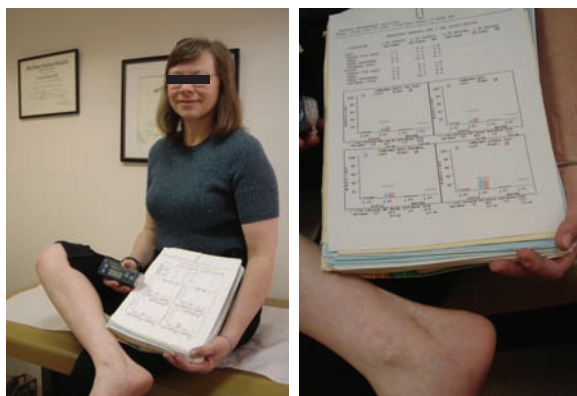


Figure 2-27. A Type I diabetic who had the Dellon Triple Nerve Decompression about 17 years ago. She holds her insulin pump in her right hand, and her most recent PSSD report in her left hand. The test demonstrates excellent sensibility in her feet. She has done a great job in maintaining her blood sugar level, and has not had any return of her neuropathy foot symptoms. She is a Registered Nurse and a Certified Diabetes Educator.

**Radoiu H, Rosson GD, Andonian G, Senatore J, Dellon AL: Comparison of measures of large-fiber nerve function in patients with chronic nerve compression and neuropathy, Journal of the American Podiatric Medical Association, 95: 438-445, 2005

“Doctor Dellon, is there somewhere I can look on the internet to learn the results of your surgery?” asked a thoughtful patient.

“Go to *NeuropathyRegistry.com*” I answered. A prospective, multi-center study group put this data on the internet as a public service of the

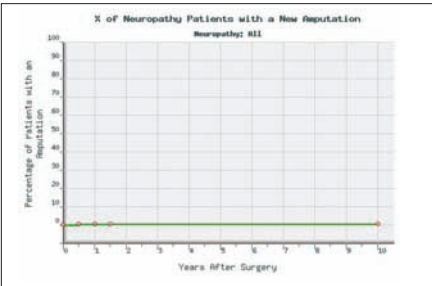


Figure 2-28. As of August 1, 2007, the limbs of 1494 patients have been operated on and there have been just 2 amputations instead of the predicted 38. 410 of these patients have had the Dellon Triple Nerve Decompression done in both legs. *NeuropathyRegistry.com*

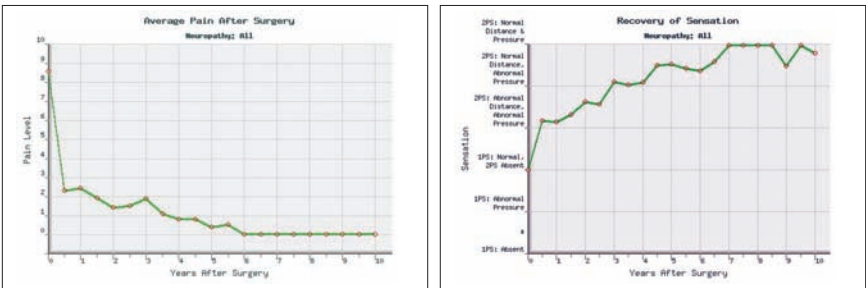


Figure 2-29. *NeuropathyRegistry.com* Outcomes for Pain Relief and Recovery of Sensation from August 1, 2007. Left: Most patients, before surgery, have a pain level of 8.5 out of 10.0 with ten being the worst pain ever experienced. By 6 months after a Dellon Triple Nerve Decompression, the average pain level is reduced to just 2 out of 10. This level of relief is maintained for many years. This graph contains 1172 patients. Right: Most patients, before surgery, have lost most ability to discriminate two points touching their big toe. Sensation recovers more slowly than relief of pain, but the graph demonstrates a steady recovery of sensation in these 1500 patients. Sensation remains improved for years.

Diabetic Neuropathy Foundation of the Southwest.” Examples of Outcomes for Pain, Sensation, Ulcers and Amputations are given in Figures 2-28, 2-29, and 2-30.




Figure 2-30. NeuropathyRegistry.com Outcomes for Ulceration as of August 1, 2007. Top: In diabetics with neuropathy, who have NOT had a previous ulceration, it is expected that one out of six (16%) will develop an ulceration of the foot or toe (red line). Among 1445 legs that had a Dellon Triple Nerve Decompression surgery, just 0.3% have had an ulceration. Bottom: In diabetics who have already had one ulceration that healed, it is expected that 50 to 60% will have that ulcer come back again or get a new ulceration (red line). Among 48 legs that had a history of a previous ulceration, and that then had a Dellon Triple Nerve Decompression, just 5.8% at 5.5 years developed a new ulceration, again demonstrating [this surgery can change the history of diabetic neuropathy](#).

“Why Do Diabetics Get So Many Nerve Compressions” & “Why Does Your Surgery Work?”

As many times as I have answered these questions by patients and as many times as I have written about this subject, I still often feel as if the answer I going to give, again, now is just too simple to be believed. And yet this is the true answer:

When sugar, the molecule, glucose, goes into the nerve to give the nerve energy to create a nerve impulse and carry a message “upstream” to the brain or “downstream” to the fingers or toes, the glucose is changed into another sugar called sorbitol. You know that sugar dissolves easily into coffee and tea. The sorbitol inside the nerve pulls water into the nerve causing water to collect. This makes the nerve itself swell. The nerves in diabetics are swollen. When a nerve swells in a tight or narrow area, as it does when it passes across the elbow, or around the side of the knee, or into the wrist or the ankle, then the nerve comes under pressure. This pressure causes blood to flow more slowly in the nerve. This decreases the oxygen in the nerve. The response to decreased oxygen in the nerve is the numbness and tingling. With time, nerve fibers do not conduct their impulses as fast, and with further time, the nerve fibers actually die. The large nerve itself can become stuck to the sides of the tunnel.

There are other factors in diabetes that make the nerve susceptible to compression. One of these is that the sugar, the glucose, sticks to the connective tissues within the nerve, to make the nerve more stiff, so it does not glide as easily. This makes the nerve more likely to get in trouble if it is stretched. Also, this process narrows the tunnels through which the nerve travels.

Finally, we know that within the nerve fiber there is something similar to railroad tracks, called tubulin, along which the building blocks, the proteins for example, travel from the cell body near the spinal cord, to the fingers and toes. In diabetes, the speed at which this transport system works is slowed down. When the building blocks, the proteins, cannot be delivered to the compressed sites along the nerve in the tight tunnels, then the nerve cannot repair itself properly.

This combination of metabolic processes is the underlying cause for the nerves in the diabetic to be susceptible to compression.

In my approach, these metabolic processes are NOT changed. Rather the tight regions of nerve compression are opened. All patients with diabetic neuropathy are NOT operated on. Patients with nerve compression at known sites of compression will be a candidate for the Dellon Triple Nerve Decompression. It is that simple.

Idiopathic Neuropathy

“Doctor Dellon,” said Jerry, “No one knows why I have neuropathy. My feet burn, sometimes like they are on fire, and sometimes they just feel heavy and dead. I do not have diabetes, will your surgery work for me?”

“Jerry, you are in great shape, and do not have diabetes, and probably will not get diabetes either. The American Neuropathy Associates estimates that there are as many people in America with neuropathy of unknown cause, or idiopathic neuropathy, as there are diabetics with neuropathy. The good news, Jerry, is that ‘Yes!,’ my approach to neuropathy also works very well for people exactly like you.”

“Jerry,” I continued, “many types of neuropathy create a condition where the nerve becomes very likely to become compressed. In diabetes, the sugar pulls water into the nerve, making it swell. As the nerve in the diabetic increases in size, it gets compressed in areas that are normally tight in the arms and legs. This susceptibility to compression can happen to you too, even though we may not understand what the exact mechanism is. You have had a skin biopsy that shows your small nerve fibers, related to pain and temperature perception, are dying, but your neurosensory testing you had with the Pressure-Specified Sensory Device™ demonstrated that your large fiber nerves, the ones related to touch and pressure sensations, are also dying. You do not have a small fiber neuropathy, but a mixed fiber neuropathy, which is quite common. So I am going to examine your legs and feet to see if we can find any sites of compression of your nerves.

Not all patients make as great a recovery as Jerry did. (See Figure 2-31.) Some patients have either continued pain, or, in some unusual cases more pain as the nerves regenerate. Nerves regenerate at one inch per month. During this painful period, some patients believe they are either not getting better or perhaps their nerve has been injured. It is therefore usual to repeat the PSSD test to document that nerve regeneration is

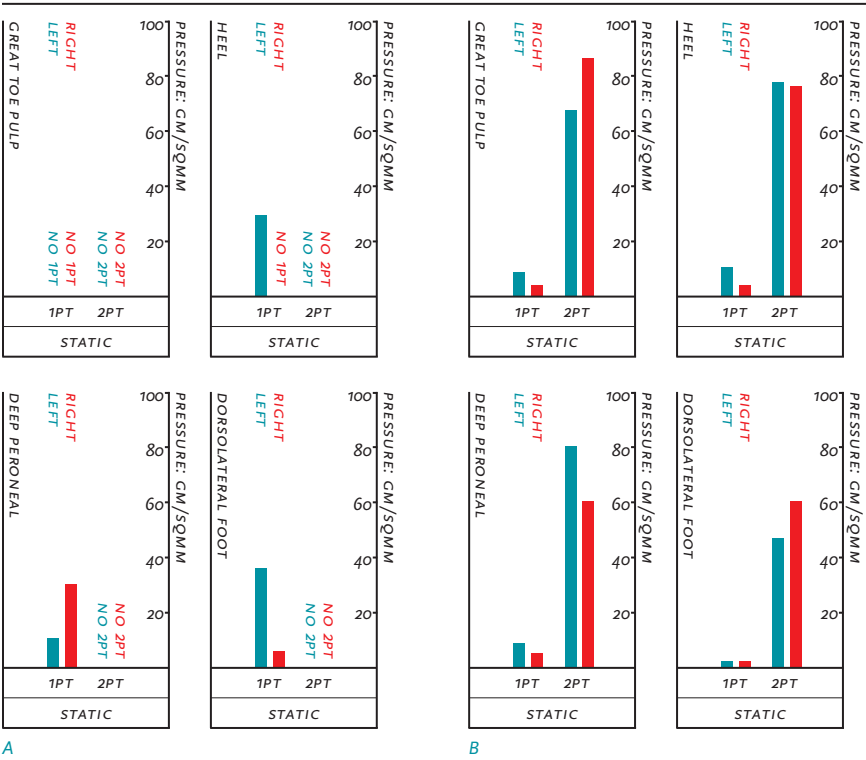


Figure 2-31. A: This man has idiopathic neuropathy with nerve compression in both legs. Note the absent blue (left leg) and red (right leg) bars related to 1PT and 2PT, demonstrating a severe degree of neuropathy with nerve fiber death. B: This test is repeated two years after the second leg had its Dellon Triple Nerve Decompression surgery. His pain is greatly relieved and he has recovered sensation as shown in the PSSD print outs, demonstrating recovery to almost normal levels of the bars for both feet for each nerve decompressed.

occurring. Another example of neuropathy improvement is documented by the PSSD test is in Figure 9-32.

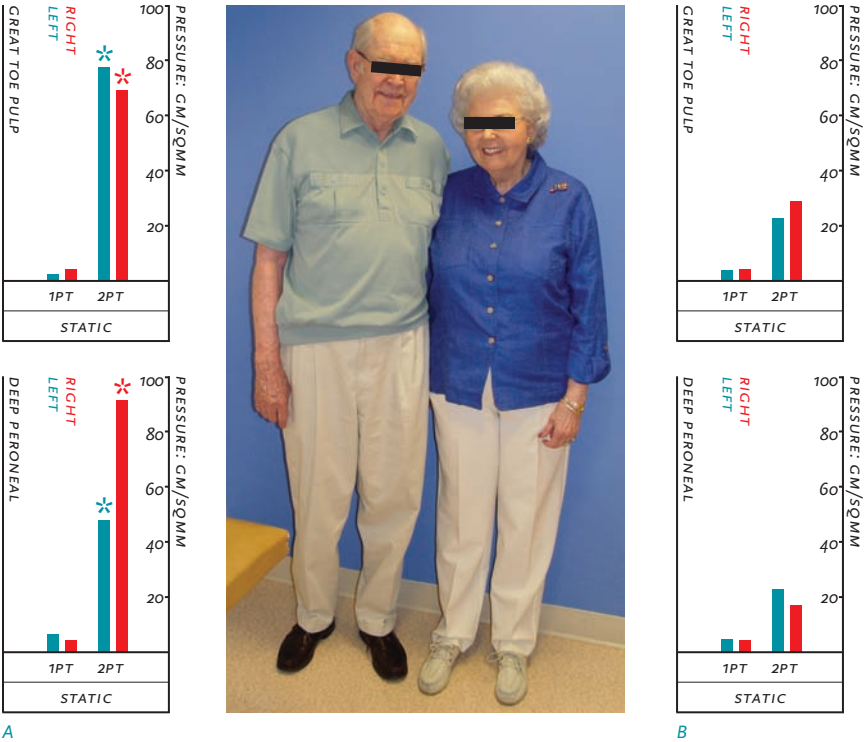


Figure 2-32. A: The woman is one year after having a Dellon Triple Nerve Decompression for idiopathic neuropathy on both legs. Her neuropathy was not as advanced as that demonstrated by the PSSD test in Figure 2-31. A: Prior to surgery, note that the bars for the left leg (blue) and for the right leg (red) are still present, but have an asterisk (*) on top of them indicating that the nerve fibers are dying. B: At one year after surgery, note that the height of the bars has diminished to almost normal levels and there is no longer an * present, demonstrating that the nerves have regenerated. This patient has improved faster than the one in Figure 2-31 because the degree of nerve compression was not as advanced. **NERVE RECOVERY IS FASTER IN SOMEONE WHOSE NERVES ARE AT AN EARLIER STAGE OF COMPRESSION. THE PSSD TEST CAN IDENTIFY THE NERVE COMPRESSION AND NEUROPATHY AT THE EARLIEST STAGE.***

*Radoiu H, Rosson GD, Andonian G, Senatore J, Dellon AL: Comparison of measures of large-fiber nerve function in patients with chronic nerve compression and neuropathy, Journal of American Podiatric Medical Association, 95: 438-445, 2005.

Chemotherapy Neuropathy

“Doctor Dellon I survived ovarian cancer only to become a painful prisoner to my feet. They hurt so much I cannot get around much,” Nancy said describing her current situation. She went on, “Doctor Dellon, the Cisplatin drug they gave me was a miracle. My cancer has been gone now for 4 years. I am a cancer survivor ... but a neuropathy cripple! I love to ski and am a Ski Patrol member, but I have no balance and cannot ski anymore. I work inspecting ski lifts, but I have been disabled now for four years due to my neuropathy. Can your work with diabetic neuropathy patients be used to help me?”

“Yes, Nancy, there is hope for you,” I told her.*

My research into chemotherapy neuropathy was begun after my work with diabetes. In the diabetes research I learned that there were problems in diabetes that made the nerve more likely to become compressed. This is also true for some chemotherapy drugs (see Table 9-1).

Table 2-1.

Vincristine Taxol Cisplatin Thalidimide

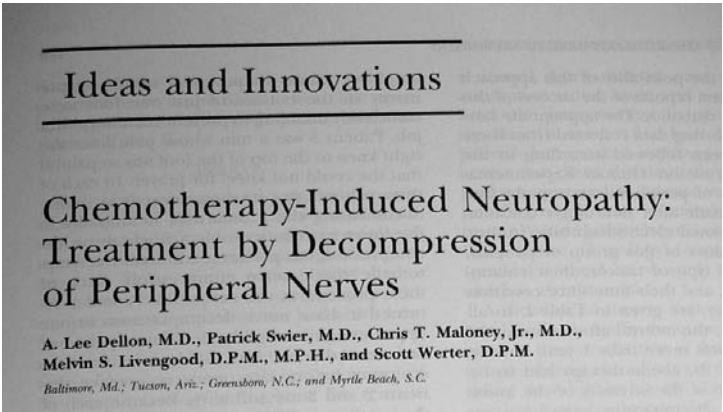


Figure 2-33. Title page of the first report of treatment of nerve compression in patients with chemotherapy-induced neuropathy, reported in 2004.

*Dellon AL, Swier P, Levingood M, Maloney CT: Cisplatin/Taxol neuropathy: Treatment by decompression of peripheral nerve. *Plast Reconstr Surg*, 114:478-483, 2004.

“Nancy,” I continued to explain, “in the hands and feet, the tight tunnels the nerves pass through at the elbow and knee, and at the wrist and ankle can create sites of compression even in a normal nerve. In the patient who has chemotherapy, some forms of the drugs attach inside the nerve and make the nerves more likely to get compressed. Surgery can release these nerves, relieve your pain and restore your sensation. Your balance may return as well.”

“Doctor Dellon, doctors helped me beat my cancer, and I want you to help me beat my neuropathy. Schedule the surgery for my first leg.”



Figure 2-34. Nancy, one year after having the Dellon Triple Nerve Decompression on her second leg. Her balance restored, her pain relieved, she is back skiing again. She says, “I AM A CANCER SURVIVOR AND I HAVE BEATEN NEUROPATHY TOO.”

“Doctor Dellon, what did my nerve look,” asked Stanley, a man who had not felt his foot for two years.

“Stanley,” I answered him, “you are the first person with chemotherapy-induced neuropathy from Thalidomide. The drug has helped your multiple myeloma cancer to stop growing, but it also has given you a painful neuropathy leaving your with numbness too. Stanley, I took a photograph of the nerve on the outside of your knee, the common peroneal nerve. The nerve had a straight line across it at the site of compression by fibrous

bands. You were born with the bands. The chemotherapy made the nerve sensitive to pressure, giving you your symptoms.” See Figure 2-35.

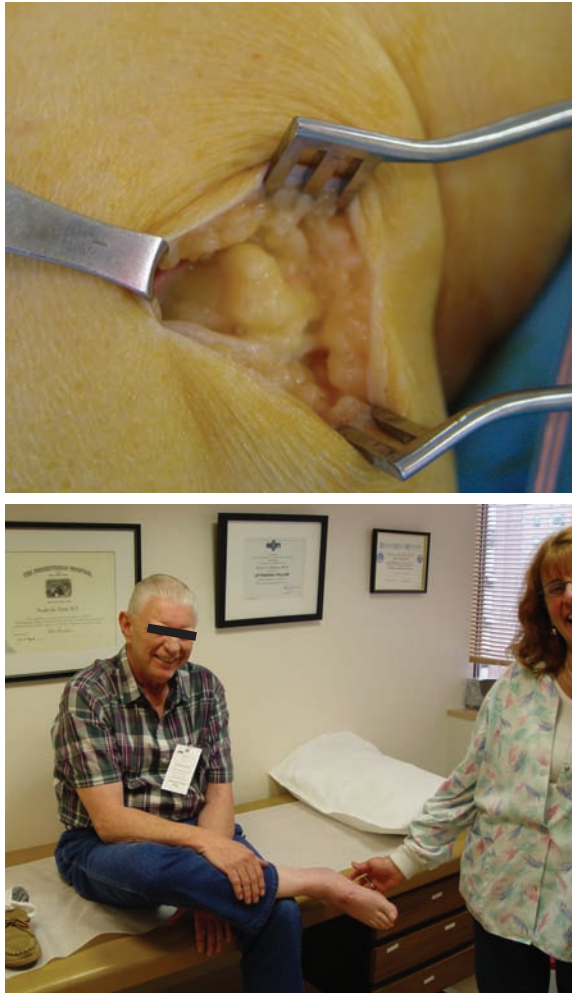

Figure 2-35. Top: The common peroneal nerve at the outside of the knee is shown during surgery. The flattened part of the nerve is noted. **The normally white nerve is now slightly yellow due to the chemotherapy, and swollen where it entered the tight area.** This nerve goes to the top of the foot (compare to other views of common peroneal nerve, Fig 1-12). Bottom: 2 weeks after a Dellon Triple Nerve Decompression, the bottom of the foot is tickled by Rita Moore in Doctor Dellon's office. **Note the patient laughing as he can now feel his foot. The tibial nerve and its branches in the inside of the ankle were released too, restoring sensation to the bottom of the foot.**

Lead poisoning was the first neuropathy to be studied experimentally. It is known that the lead causes the attachments of the cells that line the blood vessels to separate, and fluid from the blood vessels leaks out through the walls of the blood vessels. When this happens to the blood vessels in the nerves, fluid enters the nerve causing the nerve to swell. Therefore, just like in the diabetic, the nerve in the patient with heavy metal poisoning is swollen. This makes the nerve more likely to be come compressed in the tight tunnels. The Dellon Triple Nerve Decompression therefore can be effective in patients with heavy metal poisoning who also have nerve compressions.

The “heavy metals” are electronically like calcium, and have a positive charge. They are therefore absorbed and stored in the bone, and can remain there, slowly coming out over time to keep the levels in the blood high, and continuing to give you symptoms.

A laboratory test, called a heavy metal toxicity screening test, can identify if these metals are present in the blood. There are treatments that can remove these heavy metals from your body, and certainly this treatment, called “chelation therapy” should be tried first.

Leprosy

“Doctor Dellon, I have read of your work with patients who have diabetes and neuropathy. I am in charge of the Father Damien House in Guyaquil, Ecuador. We take care of people with Leprosy, which, as you know, is also called Hansen’s Disease. Doctor Dellon, even when my patients have been treated by antibiotics, and the bacteria that caused their leprosy is killed, my patients continue with numbness in the hands and feet, weakness in their hands and legs, and many also have pain. Doctor Dellon,” said Sister Annie, “can your approach to nerves help my patients? Can your approach lessen or prevent their disabilities?”

“Yes Sister Annie,” I answered her, “There is real hope for them.”

“Sister Annie,” I continued. “This is a historic day. We are here because one of my students, Dr. James Wilton, from New Hampshire, has organized this medical mission. He is a Podiatric foot and ankle surgeon. He knows

well my work with restoring sensation and preventing deformity in diabetics. I told Dr. Wilton about Dr. Paul Brand's pioneering work in Leprosy in India in the 1940's and 1950's, in which he demonstrated that the loss of tissue in leprosy was due to loss of sensitivity. He demonstrated that the nerves become involved close to joints. I suggested to Dr. Wilton that my work with diabetics could be transferred to leprosy patients. Just as you have said, the bacteria that cause leprosy are treated well now with antibiotics. But the bacteria attach to nerves in regions of the nerves close to the skin, and the body's reaction to the bacteria cause the nerve to swell. I believe that the progressive deformity in leprosy is due to chronic nerve compression, and that the operative approach I have developed for diabetic nerve entrapments will work in leprosy."

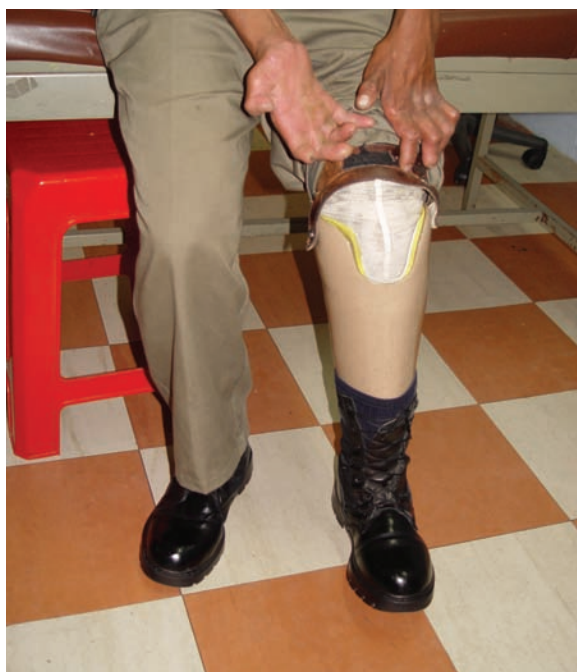

Figure 2-37. Leprosy Patient. Note that the left leg has been amputated due to ulceration resulting from loss of sensation, similar to what occurs in the diabetic with neuropathy. Note the hand deformities due to bilateral median and ulnar nerve compressions, not Leprosy.

In July of 2004, Dr Wilton, and David Seiler, who is the Director of Neurosensory Training for the Dellon Institutes for Peripheral Nerve Surgery®, made a survey trip to the Father Damien Foundation in Guyaquil, Ecuador to do neurosensory testing and physical examinations on patients who had been treated with antibiotics for leprosy but who still had symptoms in the hands and feet, and had progressive disability. David Seiler and I have worked together in research since 1982.

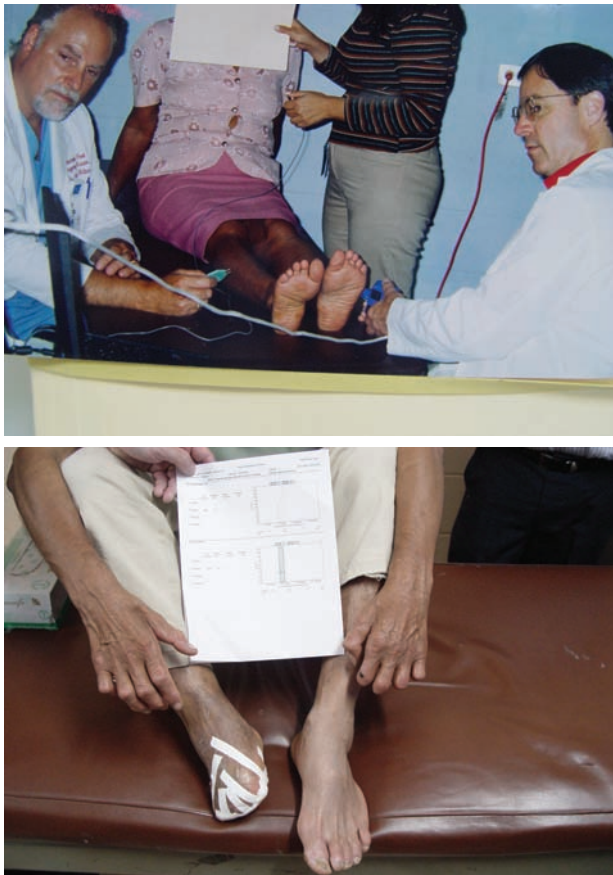

Figure 2-38. Top: Dr James Wilton (left) assisting David Seiler in neurosensory testing with the Pressure-Specified Sensory Device™ in Guyaquil, Ecuador, July 2004. Bottom: A patient with his PSSD test result. Note the amputated right toes and left fingers due to loss of sensation. Would appropriate nerve decompression earlier have prevented this?

My approach to nerve problems in leprosy followed from my approach to nerve problems in the diabetic.

The double crush concept implies that one site of compression predisposes a nerve to a second site of compression. A metabolic problem like diabetes could be the first “crush.” In leprosy, the attachment of the bacteria could be the first “crush.” Then each other site along the nerve needed to be decompressed. So for the median nerve in the upper extremity, decompression needed to be done at the wrist and the forearm, for the ulnar nerve at the wrist and the forearm. While historically, surgeons had tried to decompress the ulnar nerve at the elbow, my approach included the submuscular transposition, described in Chapter 1, plus an internal neurolysis of the ulnar nerve at the elbow, and the neurolysis of the ulnar nerve at the wrist at the same time. Furthermore, at the wrist, the motor branch of the ulnar nerve was separately released. A similar approach was taken in the lower extremity.

In order to minimize the number of operations per patient, and to minimize their time under anesthesia, the plan was for Dr. Wilton to operate on a leg while I operated on an arm at the same time.

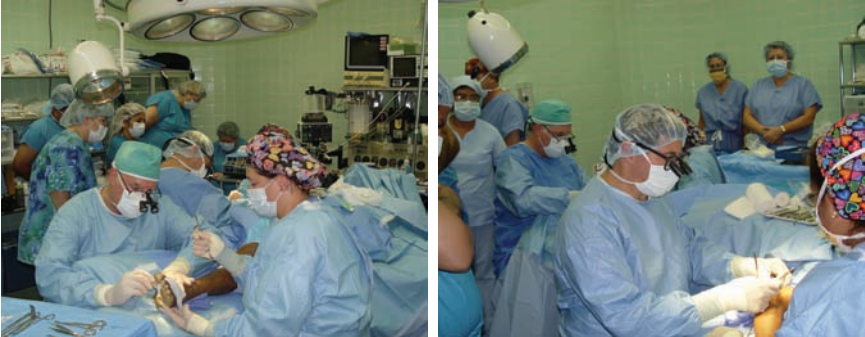

Figure 2-39. Left: The team operating in Ecuador for the first time. Note Dr. Wilton, green hat, operating on the foot in the lower left, with Dr. Dellon directly behind him operating on the right arm. Dellon Triple Nerve Decompressions were done in the arm and in the leg. Right: Another patient, with Dr. Dellon in foreground operating on the left elbow, and Dr. Wilton behind Doctor Dellon, doing a Dellon Triple Nerve Decompression.

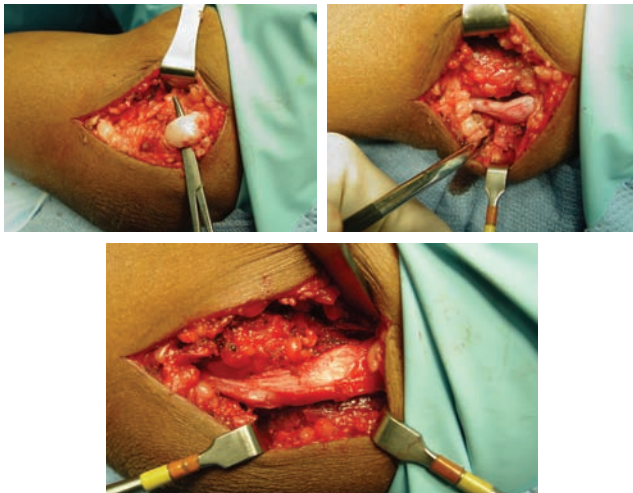


Figure 2-40. Ulnar nerve decompression in a patient with leprosy. Top left: Note the huge size of the ulnar nerve above the elbow. Top right: After release of the cubital tunnel, in which the ulnar nerve is compressed behind the elbow, note the narrow area of nerve compression. Bottom: After microsurgical neurolysis of the ulnar nerve. The nerve was then transposed into a submuscular position using Dellon musculofascial lengthening technique.

The first surgical expedition to apply this approach to leprosy was in November 2004.

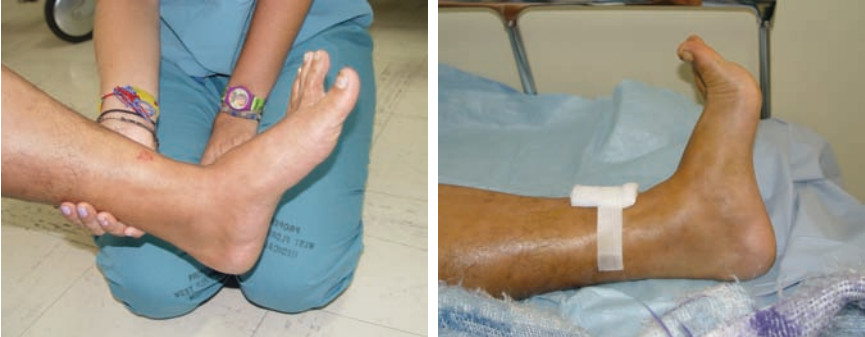

Figure 2-41. Leprosy patient with a peroneal nerve palsy. Left: Prior to surgery, the patient could not lift up his foot or his big toe. Right: In the recovery room, right after decompression of the common peroneal nerve at the knee, the patient can now lift up his foot and extend his big toe. This is a reversal of a paralyzed leg in this leprosy patient.

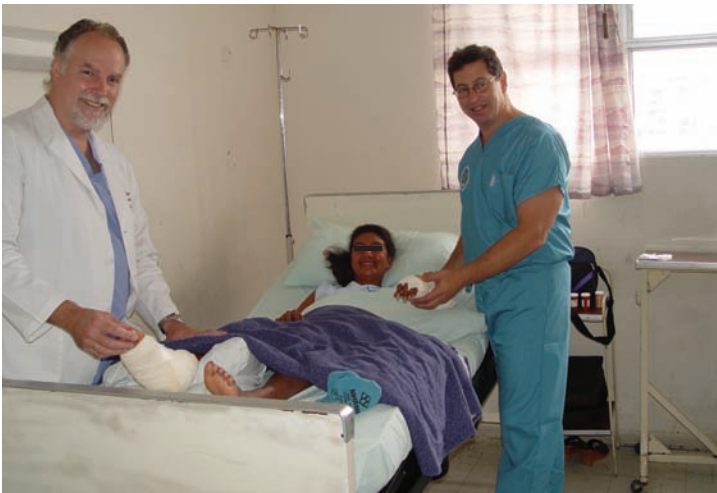

Figure 2-42. Dr. Wilton, left, and Dr. Dellon, right, tickling the toes and the fingertips of this young woman with leprosy. She had a Dellon Triple Nerve Decompression on left hand and right leg. The day after surgery, she smiles as she can feel again.

The Dellon Institutes for Peripheral Nerve Surgery® has sent continued this work which has been sponsored by the Perfect World Foundation. In a subsequent trip, Dr. Scott Nickerson, an Orthopedic Surgeon (Figure 2-3), joined the trip with his wife to carry out an independent analysis of the surgical results. And Dr Christopher T. Maloney Jr, MD, a Plastic Surgeon, from Tucson, joined the mission with his father, Christopher T. Maloney Sr., MD, a retired Cardiac Surgeon. The most recent mission was in November 2006. The work is successful and continues.



Figure 2-43. Dr. Christopher T. Maloney Jr., MD, a Plastic Surgeon from Tucson, and his father, a retired Cardiac Surgeon, operated together on the leprosy patients. They are shown here on the cover of the local medical society news.



Figure 2-44. Dr. Julia Terzis, MD, PhD, left, and Dr. A. Lee Dellon, MD, right, with their awards from the Plastic Surgery Educational Foundation in 2005. Dr. Terzis received her award for work with obstetrical palsy, and Dr. Dellon for his work with leprosy. Both Dr. Terzis and Dr. Dellon have been President of the American Society for Peripheral Nerve, and of the American Society for Reconstructive Microsurgery

Communicating Success To Different Communities

In the most professional manner, it is critical to educate physicians and the public alike about our success relieving pain, restoring sensation, and preventing ulcers, infections, and amputations in those patients with neuropathy.

I have been trying to do this for more than 20 years.

May I tell you about the most important experimental work, which was published in the early 1990's? After making the observations that I could help my neuropathy patients if they had a nerve compression present, I studied this problem for 6 years in diabetic rats. What if there were a group of rats that did not have a site of compression, would they develop neuropathy as the diabetic rat usually did? Neuropathy in the rat is identified by measuring the rat's footprints after their feet have been put in water-based paint.



Figure 2-45. Dellon Institutes for Peripheral Nerve Surgery® logo includes the rat footprint, used to measure neuropathy experimentally, as a symbol of our continuing research and a reflection of our motto: “Being Academic in Private Practice™.” There are three other icons in the logo. The PSSD is at the top, the book stands for scientific publications, and the loupes represent microsurgery.

Results of this study* can be seen in Figure 2-46.

Doing the same operation in rats that I did in my patients **changed the natural history of diabetic neuropathy in this species of rat!**

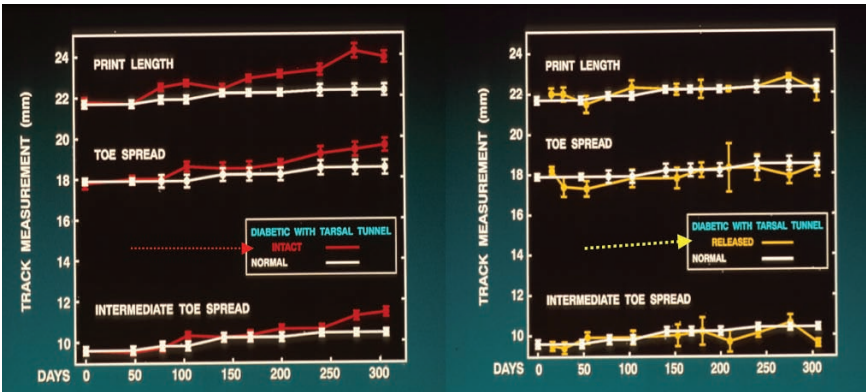


Figure 2-46. **DIABETIC RATS WITHOUT A TARSAL TUNNEL DO NOT DEVELOP NEUROPATHY.** Results of an experimental study in diabetic rats. Each rat has a blood sugar of 400. The study lasted for one year. The white lines are the measurements of the characteristics of the foot of a normal, non-diabetic rat. Left: The red lines are those same measurements in the diabetic rat with a tarsal tunnel. As the red lines separate from the white lines, it demonstrates that diabetic rats, with their normal tarsal tunnels, have a progressive, neuropathy and have trouble walking normally. Right: The yellow lines are those same measurements in diabetic rats who have no tarsal tunnel (they were released at the beginning of the study), and these diabetic rats have footprints that look just like the non-diabetic, normal (white line) rats. The diabetic rats without a tarsal tunnel, without a site of compression, did not develop neuropathy.

*Dellon ES, Dellon AL: Functional assessment of neurologic impairment: Track analysis in diabetic and compression neuropathies. *Plastic Reconstructive Surgery* 88:686-694, 1991
*Dellon ES, Dellon AL, Seiler WA IV: Effect of tarsal tunnel decompression in streptozotocin-induced diabetic rats. *Microsurgery* 15:265-268, 1994.

This is the story we must bring to people everywhere: **THERE IS HOPE AND OPTIMISM FOR THE DIABETIC WITH SYMPTOMS OF NEUROPATHY IF THERE ARE COMPRESSED NERVES THAT CAN BE DECOMPRESSED WITH SURGERY.**

To get the word out to the community, each patient who has been improved will speak to their doctors and friends to let them know there is now hope for them. I try to speak to groups in the community. Figure 2-48 is an example of this. I spoke for a retirement community to give them hope.

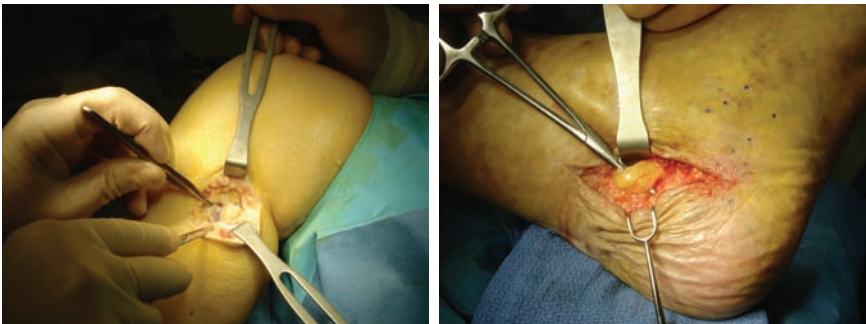


Figure 2-47: Diabetic with neuropathy Left: Note swollen yellow common peroneal nerve at knee entrapment site. Right: Note swollen yellow tibial nerve in the tarsal tunnel at entrapment site, crossing over the clamp. **It is this swelling in the nerve that makes it so susceptible to nerve compression at these sites of anatomic narrowing. The areas of tightness can be opened in surgery, as shown above.**



Figure 2-48. Luiann Olivia Greer, my wife, with her mother JoAnn and her father Jack Greer and myself at Willow Valley Retirement Community at the time of my lecture. More than 10% of people over the age of 65 will have neuropathy from one cause or another.

The goal of the United States of America for the year 2000 was to reduce the amputation rate by 40%. That goal was not met. Now it is the goal of Healthy Choice USA for 2010. (see amputation rates in Table 2-2).

We need to get the message out that if you have a Dellon Triple Decompression surgery, your rate of amputation will approach 0%

Table 2-2.
AMPUTATION RATES 1994 (*per 1000 of population*)

African Americans	9.3
Caucasians	5.7
Male	10.9
Female	6.2
Under 64 years old	6.5
Between 65-74 years old	10.2
Over 74 years old	11.9
Hispanics	unknown
Native Americans	unknown




Figure 2-49. It is the stated goal for the United States of America to reduce the amputation rate by 40%. But there is no approach that has been successful so far except the approach that I have described here.

Public Service at Community Diabetic Expos

The Dellon Institute for Peripheral Nerve Surgery in Boston participated in 2005 in the Diabetes Expo sponsored by the American Diabetes Association. Free neurosensory testing of the feet of diabetics was done. (see Figure 2-50). In June of 2006, Doctor Dellon was invited to participate in the program of the American Diabetes Association annual meeting, in Washington, DC. A report is available on Dellon.com.



Figure 2-50. The Boston Dellon Institute is directed by Dr Virginia Hung, (left) with Vicki Muse, RN, CDE. Vicki and Gina Andonian, (right) came from the Dellon Institute in Baltimore to do the neurosensory testing for Dr Hung in Boston.

The Native American Community

The amputation rate of the Native American community is probably the highest rate in the United States. It is somehow conveniently “unknown.” In 1997, I went to the T’ohono Odham nation outside Tucson, Arizona at the request of the Podiatrist of the Indian Health Service in order to help them with this problem. Bringing help to people can be a challenging problem.

The biggest success has come with the Gila Reservation, between Tucson and Phoenix, where a group of very proactive Podiatrists, under the leadership of Wes Yamada, DPM have introduced neurosensory testing with the PSSD and have taken my Advanced Lower Extremity Peripheral Nerve Workshop, learning the technical skills necessary to do the Dellon Triple Decompression to their population of diabetics. It is the Gila reservation where the original distinction of Type I and Type II diabetics occurred.

In August of 2005, I spoke before the Association of American Indian Physicians in Washington, DC, and in July of 2006 at the Headquarters of the Indian Health Service in Rockville, Maryland. *I am hopeful that soon the success of my work in other populations of diabetics can be duplicated on for the Native Americans.*

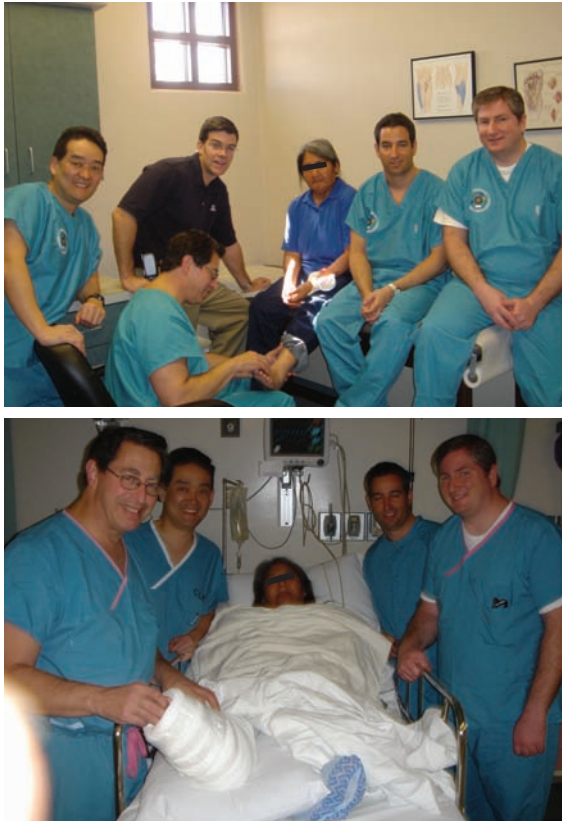

Figure 2-51. The first Native American diabetic patient from the Gila Reservation in Arizona at the University Medical Center of the University of Arizona. Top: She is being examined by me prior to surgery. In the black shirt, is Dr. Christopher T. Maloney, Jr, MD. Surrounding us are the Podiatric foot and ankle surgeons from the Gila Reservation from Sacaton, Arizona. Clockwise from the left: Wes Yamada, Wes Taxier, and Paul Keller. Bottom: In the recovery room immediately after the Dellon Triple Nerve Decompression on her right leg, the patient smiles as she can feel her foot again. Her group of Podiatrists from the Gila Reservation surround her.

The International Community

DOCTOR DELLON TRAINED SURGEONS WHO ARE PROVIDING PATIENTS WITH THIS SURGERY IN 18 COUNTRIES. SOME OF THESE DOCTORS ARE SHOWN HERE.

AUSTRIA

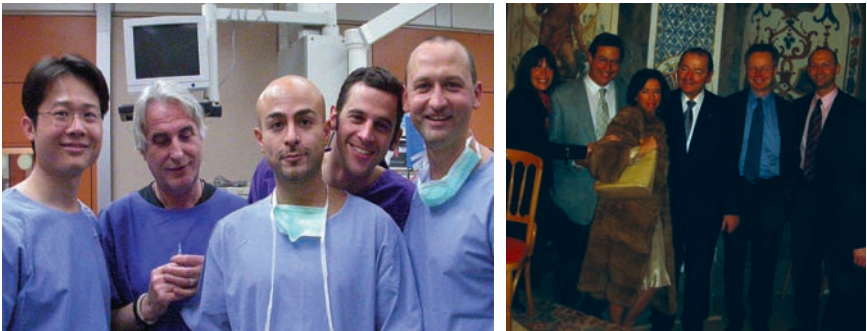

Figure 2-52. Left: Oskar Aszmann, MD, Associate Professor of Plastic Surgery at the University of Vienna (surgeon on the right end) is shown with his laboratory staff in 2006, and (right) with Doctor Hanno Millesi and his wife Dagmar, also a Plastic Surgeon, at Dr. Millesi’s 2006 Symposium on Peripheral Nerve Surgery, at which Dr. Dellon (left with wife, Luiann) presented world results of the Dellon Triple Nerve decompression surgery. Dr. Aszmann is the pioneer to introduce this work into Austria. They are shown at a Mozart concert in the historic hall in which Mozart’s music was originally played.

BRAZIL



Figure 2-53. Marcus Castro Ferreira, MD, Chief of Plastic Surgery in Sao Paulo, Brazil, with Doctor Dellon at a meeting in 2005. Doctor Ferreira is his their country’s pioneer in introducing the Dellon Triple Nerve Decompression surgery and neurosensory testing into his country.

ENGLAND



Figure 2-54. Top: Doctor Nicholas Parkhouse, the Plastic Surgeon in charge of the McIndoe Plastic Surgery Clinic in East Grinstead, United Kingdom, is the Director of the Dellon Institute for Peripheral Nerve Surgery in England. He is shown above with Dr. Dellon. Bottom: Doctor Sally Stevens is shown between Doctor Dellon and his wife Luiann in London, where she did her research on the evolution of the knee joint. They are at the Guild Hall honoring the Chinese New Year in January of 2006.

CHINA



• 182 •

Nervous Diseases and Mental Health, 2005, Vol. 5, No. 8

• 论著 •

应用外周神经减压术治疗 2 型糖尿病性周围神经病

姚 勇 王任直 张 波

【摘要】 目的 探讨应用外周神经减压术治疗 2 型糖尿病性周围神经病的疗效。方法 采用腓总神经、胫神经及腓后神经三处外周神经减压术治疗 46 例临床表现为双下肢对称性麻木、疼痛及感觉异常的 2 型糖尿病性周围神经病患者,并进行回顾性分析。结果 术后下肢麻木症状明显缓解 69.6% (32 例),缓解 23.9% (11 例),无变化 6.5% (3 例)。术后下肢疼痛症状明显缓解 36.8% (14 例),缓解 57.9% (22 例),无变化 5.3% (2 例)。结论 外周神经减压术对于 2 型糖尿病性周围神经病的自发性疼痛、麻木有较好疗效。

【关键词】 外周神经减压术 糖尿病性周围神经病

Treatment of Symptomatic Diabetic Peripheral Neuropathy by Surgical Decompression of Three Peripheral Nerves Yao Yong, Wang Renzhi, Zhang Bo. (Department of Neurosurgery, Peking Union Medical College Hospital, Peking Union Medical College, Beijing 100730, China)

Figure 2-55. In 2005, Doctor Yong Yao, a neurosurgeon on the faculty of Peking Union Medical College in Beijing, came to the Baltimore to study with Doctor Dellon. Doctor Yong Yao is pictured standing with Doctor Dellon in front of the Johns Hopkins Hospital in Baltimore, where Doctor Dellon is a Professor of Plastic Surgery and Neurosurgery. Doctor Yong Yao began to do the Dellon Triple Nerve Decompression in China in the Department of Neurosurgery of Professor Wang. Their first publication of Dr. Yong Yao's results is shown above from the Nervous System and Mental Health Journal. In January of 2007, Dr. Yong Yao presented the results of his first 100 Dellon Triple Procedures at the American Society for Reconstructive Surgery meeting. Doctor Yong Yao is the Director of the Dellon Institute for Peripheral Nerve Surgery in China.

DUBAI



Figure 2-56. In 2006, the Dellon Institute for Peripheral Nerve Surgery opened in Dubai, United Arab Emirates. Articles appeared in the Dubai press. Lower left: Gordon Pincock, CEO of the Sulaiman Al-Habib Medical Group, Dubai, UAE, is shown with Doctor Dellon and his wife, Luiann. Lower right: Doctor John Bouillon, on the right, an Orthopedic surgeon who trained at Johns Hopkins with Doctor Dellon, is shown operating with Doctor Dellon at the International Modern Hospital in Duabi. Dr. Bouillon is the Director of the Dellon Institute in Dubai, where the Dellon Triple Nerve Decompression will be able to help the large Emirate population of diabetics. Under direction also of Dr. Bouillon and the Habib Medical Group, this surgery will be done at the American Surgical Center, the first outpatient surgical center in the region. The Dellon approach to peripheral nerve problems will soon be available in Abu Dhabi.

ITALY



Figure 2-57. Top Left: The first Wound Healing meeting in Rome, directed by Dr. Professor Nicolò Scuderi, Chief of Plastic Surgery, University of Rome School of Medicine. Dr Dellon spoke on the Triple Nerve Decompression surgery preventing ulceration and amputation. Luiann is with him, March 1, 2006. Top right: Agrigento, Sicily, where Luiann and Lee identify with the reconstruction of the ancient ruins, just as his surgery can restore lost sensibility to the foot. Bottom: Doctor Fabio Quatra, a Plastic Surgeon who trained with Doctor Dellon, is interviewed for TV as he introduces the Dellon Institute for Peripheral Nerve Surgery to his city, Palermo, Sicily, where he will be its Director. Dr Fabio Quatra combined with Dr Dellon to write a chapter on “Decompression of Peripheral Nerves in Patients with Diabetic Neuropathy” for the first on-line electronic book on Plastic Surgery, edited by Fabio Santanelli and Nicolo Scuderi, “*Chirurgia Plastica Ricostruttiva Ed Esthetica*” from the University of Rome “La Spienza”, published in Italian in June of 2007.

INDIA

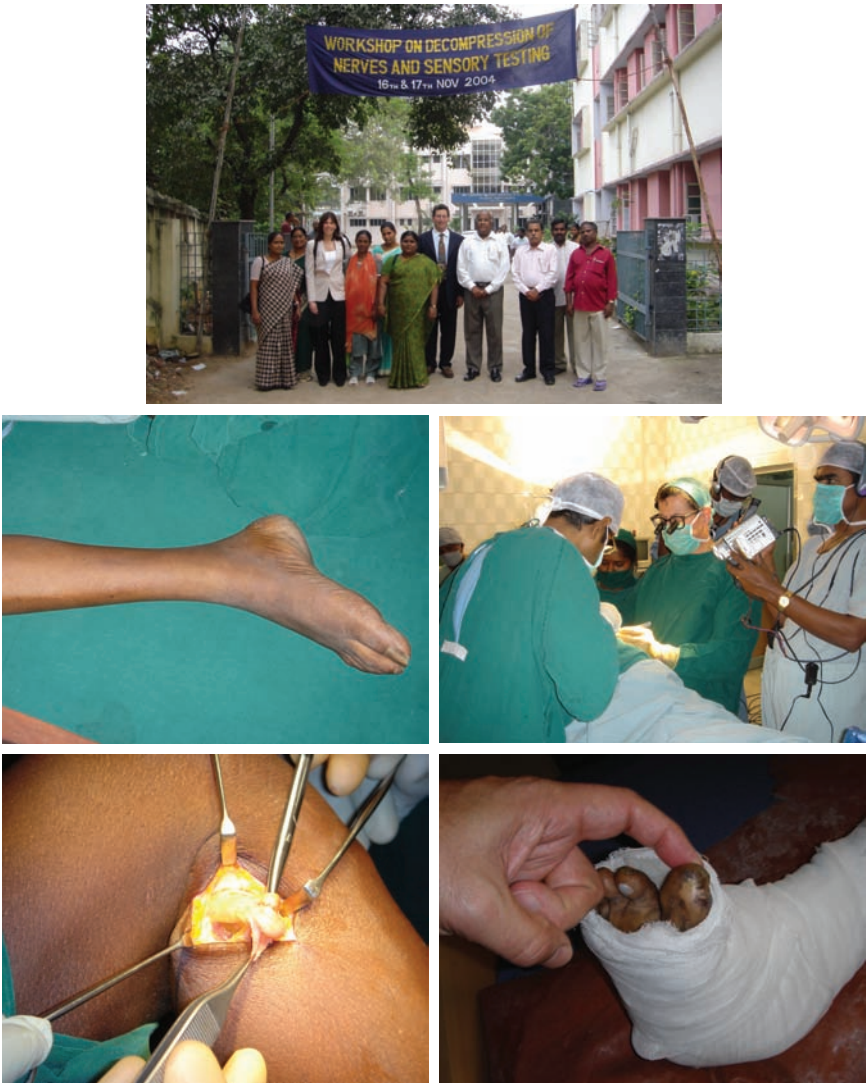

Figure 2-58. Top: Doctor Dellon teaching and operating in Chennai (Madras), India in 2004 at the invitation of Doctor G. Balakrishnan, Chief of Plastic Surgery at the Stanley Government Hospital (center next to Doctor Dellon). Center left: The paralyzed foot of a patient with leprosy. Center right: Doctors Dellon and Balakrishnan operating on this patient. Bottom left: The thickened and scarred peroneal nerve at the knee is decompressed. Bottom right: The next day, the patient can begin to lift up his big toe, as the paralysis reverses after the surgery.

INDIA




Figure 2- 59. Top left: In Mumbai (Bombay), India, at the invitation of Doctor Suresh Tambwek, Chief of Plastic Surgery at Bombay Foundation Hospital, Doctor Dellon did his Triple Nerve Decompression surgery on a diabetic. Dr. Tambwek (center in white) has been the leader to introduce this surgery into India, and has published one paper on his results. Top right: This woman came to the United States for Dr. Dellon to operate on both arms and both legs to treat her diabetic neuropathy related to nerve compression. She is at a reception honoring Dr. Dellon in Mumbai. Bottom: After Doctor Dellon spoke for the Indian Association of Plastic Surgery about his neuropathy work, in 2004, he and his wife, Luiann, visited the Taj Mahal in Agra, India. Across from the entrance to the Taj Mahal is a lepersarium.

TURKEY



Figure 2-60. Dr Dellon spoke at the Turkish Society for Plastic and Reconstructive Microsurgery, invited by Fuat Yuksel, MD, a Plastic Surgeon from Istanbul (city symbol, upper left). Upper right: Program cover for the meeting. Dr Yuksel, through his own research, confirmed Dr. Dellon's basic science and clinical research with the Triple Nerve Decompression for Diabetic Neuropathy. He is at left with the Dellons, as the Neurosensory testing device is displayed (center left) at the meeting and below, on the left, with Plastic Surgeons, Ferit Demirkan, Dr. Dellon, Yavuz Demir, and Alper Sari. Center right: Dr. Dellon giving his lecture at the meeting.

Pain Solutions Summary

Traditional medical teaching is that neuropathy is “progressive and irreversible,” which means that if you have neuropathy you are not likely to get better. This is especially true for neuropathy in diabetics.

The news is that through years of my research, which has now been confirmed by many other doctors throughout the world, we know that *in many patients with neuropathy the symptoms are due mostly to compression of nerves in the arms and legs, hands and feet*. The best news is that nerve compression sites can be decompressed surgically to remove the pressure on the nerves that are causing the symptoms.

IF YOU HAVE A NERVE COMPRESSION ASSOCIATED WITH YOUR NEUROPATHY, THEN YOU SHOULD HAVE AN 80% CHANCE TO RELIEVE PAIN AND RECOVER SENSATION BY NERVE DECOMPRESSION SURGERY. *When this improvement occurs, your balance will improve, and you will then no longer be at risk for ulceration or amputation.*

There is hope for you. Visit Dellon.com or call +1 877-DELLON-1 (+1 877-335-5661) for more information.

