

---

3

---

---

---

# Chapter Three

## Joint Pain

---

---

“Joint pain might be due  
to a nerve injury.”

---

---

## Top Secret Meeting of the Joint Chiefs

The Chairman of the International Joint Chiefs was about to open the *top secret* meeting. Those able to attend the meeting in Switzerland, a neutral\* country, are listed in Table 3-1.

Table 3-1. ATTENDANCE LIST OF JOINT CHIEFS MEETING; SWITZERLAND.

THE CHAIRMAN:

Eye Nose It-all, PhD (Anatomy), Italy

UPPER EXTREMITY:

Professor Doctor Shul der-Pien, MD, Holland

Doctor El-bow, Hurts-Alloviya, Spain

Barren Dr. Rist Ge Plotzen, Schmerze, Austria

LOWER EXTREMITY:

Le Docteur Knock Knies, MD, Tooloose, France

Sir Aincle Sprainagain, MD, Laxity, England

The Chairman introduced the subject, “Each of you Chiefs of Service is responsible for diagnosis and treatment of musculoskeletal pain in your unique, specialized, anatomic region. As you know, **musculoskeletal pain demands that we assess the function of the ligaments, the bones, the cartilage, the muscles, and the very joints themselves.** And we are excellent with this approach. Of course,” Doctor Nose It-all , continued, “there are always patients with real pain for whom our x-rays, our MRIs, and our traditional testing, say ‘Normal.’ The patient then may still come for surgery, for endoscopy, for joint replacement or fusion. We are usually excellent with this approach. But, *there are always the patients with persistent real pain.* And then, there is always **referral to pain management.** Yes, we are usually excellent with this approach too. **But pain management represents our failure to understand the underlying source of the pain. It might be outside the musculoskeletal system!**”

\*Switzerland reportedly neither accepts nor denies the existence of nerves in joints but supports the right to investigate this matter further and bring it to the public’s attention.

“Fellow Joint Chiefs, I now report to you the **good news**. Recently there was a report on the internet by Doctor Dellon that claimed **joint pain might be due to a nerve injury!** And I believe it too! We have all been missing something very important for our patients’ pain relief. **We must learn from Dr. Dellon’s research. Please study his writings,**” he concluded. “Then we will meet again to discuss this matter.”

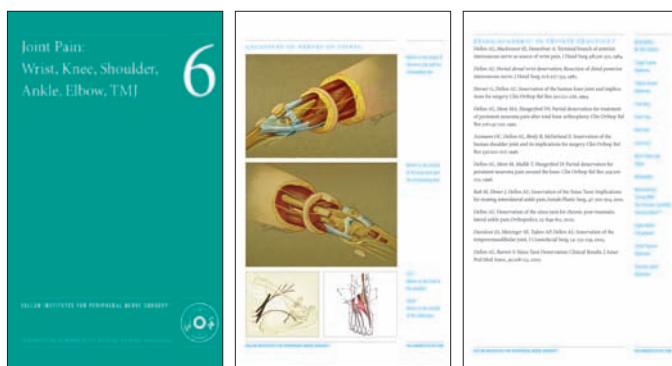


Figure 3-1. Brochure #6 from Dellon.com on Joint Denervation. This Brochure describes the scientific approach that I developed to treat joint pain and preserve joint function.

## Partial Joint Denervation

“Doctor Dellon, **I fell and hurts my wrist**. The Orthopedic surgeon took x-rays. There were no fractures, but it really hurt. So he told me that I had badly sprained my wrist, and I had loose ligaments. **He put me in a cast for three weeks so my torn ligaments could heal. But I still had pain.** So he operated on me to tighten up my ligaments. That was two years ago! **I still cannot move my wrist up or down without pain.** Can you help me?” asked Valerie, a 26 year old woman. “It is my left hand and I am left handed. I have trouble writing even dressing my self,” she added, frustrated.

“Yes, I can help you,” I told her, “There are a group of small nerves that go to the wrist ligaments.. **They now can be identified and removed.**”

“Will I still be able to move my wrist after that? Will I loose the feeling in my fingers after you remove those nerves,” Valerie asked, worried.

“Your pain will be gone because I will remove just those nerves that were hurt when you fell. They only go to the ligaments of the joint. Those nerves do not control movement or sensation in the hand. They only send pain messages from the joint. **The pain message will stop when I remove those damaged nerves.** When your torn ligament healed, the nerves became stuck in the scar, forming a painful neuroma. My surgery will remove those damaged nerves,” I explained.

“Doctor Dellon, why didn’t the damaged nerves show up on the x-rays? Why didn’t my Orthopedic surgeon tell me about these nerves?”

“Valerie,” I answered her, “These nerves are too small to be seen by x-ray, and they are not even in any anatomy books the Orthopedic Surgeon, or even myself have studied. Valerie, beginning in 1977, I began to study the nerves to our joints. Fortunately, **I have been able to learn about the location of the nerves to the wrist, then the knee, the shoulder, then the ankle and now the elbow. It is now possible to find these nerves and remove them, relieving pain in the joint and permitting the joint to move without pain.**”

“Doctor Dellon, how can you prove to me that you are right about why my wrist hurts?” Valerie asked, skeptical that nerves that were not in the anatomy books could really be the source of her pain.

“Valerie, here is the process we use. I will put a local anesthetic near the nerves I suspect are causing your pain. I will not put the local anesthetic into the joint itself. The you can see if your pain goes away, and if you can move your wrist better. If that happens, then we will have about a 90% chance of relieving your pain by removing the nerve that I block. Sometimes, for the wrist, two different nerves are injured, and I have to remove them both.”

---

DOCTOR DELLON WON THE PLASTIC SURGERY EDUCATIONAL FOUNDATION SENIOR INVESTIGATOR RESEARCH AWARD IN 2005 FOR HIS CONCEPT OF PARTIAL JOINT DENERVATION.

“The nerve block,” I continue, “is proof that if I remove the nerve it will not affect your ability to move your wrist and you will see that you do not lose sensation.” (See Figure 3-2.)

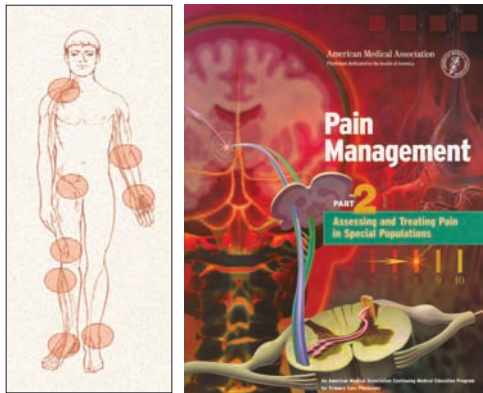


Figure 3-2. If a joint is injured in any part of the body, like the circled areas on the left, then the message from the nerves in that joint travel to the spinal cord, and then on to the brain, as illustrated on the right. **The brain receives a message it interprets as joint pain.** If a bone is not broken, but the nerve to the joint is stuck in the healed ligament of the joint, the brain understands that the joint hurts. If the joint has been removed and replaced, and the nerve to the original joint becomes stuck in scar around the joint replacement (the implant), then the brain receives a message of joint pain even in the absence of a joint.

Table 3-2. PRINCIPLES OF PARTIAL JOINT DENERVATION.

1. If your brain perceives pain in a joint, then that message is transmitted by a nerve
2. If the anatomy textbooks do not show nerves to a joint, then research can be done to identify those nerves. They do exist.
3. If the nerves to the joint can be found, then pain relief can be demonstrated by a local anesthetic nerve block.
4. If pain relief is possible by a nerve block of the nerve to the joint, then a surgical approach can be planned to remove that nerve.
5. If pain relief is possible by partial joint denervation, then joint function can be saved.
6. The above approach assumes that musculoskeletal structures have been restored, and the joint has structural stability.

## The Wrist Joint

Valerie had a partial wrist denervation. In Figure 3-3, you can see her during our consultation and In Figure 3-4, you can see her **improved wrist range of motion, which is now pain free.**

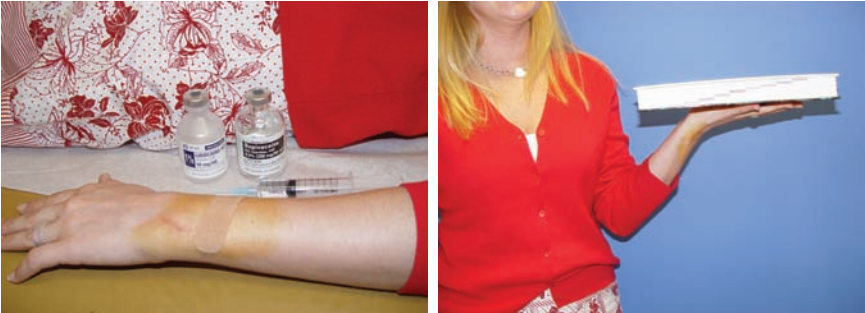


Figure 3-3. Two years after a wrist sprain and ligament reconstruction, Valerie still has severe left wrist pain. On the left, her wrist is seen after local anesthetic block of the nerves to the wrist joint. On the right, 10 minutes later she is able to hold a heavy book against gravity without wrist pain. This successful wrist block indicates that she is an excellent candidate to have a partial wrist denervation procedure.



Figure 3-4. Valerie is shown 3 months after surgery flexing and extending her wrist without pain, holding a 7 pound weight. Her partial wrist denervation has been a success. Scars are from the original orthopedic surgery to stabilize her wrist. See Figure 3-5.



## Wrist Assured of Pain Relief

Doctor Wilhelm, in Germany, in the 1960's began the modern era of wrist denervation. However, he believed that 5 incisions and 10 nerves needed to be removed. In 1979, I described the nerve to the back of the wrist joint and in 1984 the nerve to the front of the wrist joint. Today, total wrist denervation is still done for wrist pain, primarily in Europe. In papers in 1984 and 1985, [I introduced the concept of just removing either the nerve to the front, or the nerve to the back of the wrist joint, as determined by nerve blocks.](#) Today, both of these nerves can be removed through a single incision in the back of wrist. If wrist structure is strong, a long lasting result with improved function can be achieved. In Figure 3-3, the nerve block to the wrist with immediate relief of pain and improved function is demonstrated, and in Figure 3-4, the improved wrist function is demonstrated at 3 months. In Figure 3-5, a ten year result is illustrated.

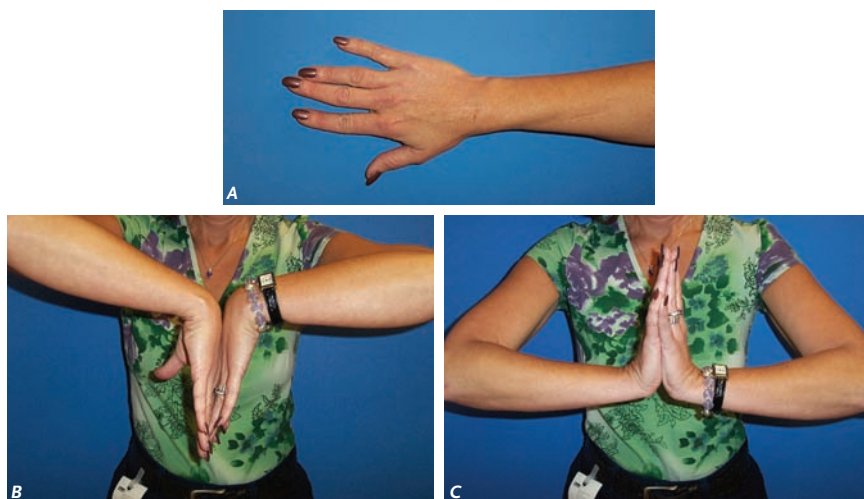
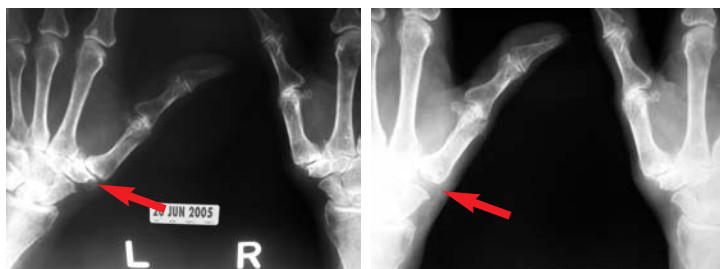

Figure 3-5. Ten years after wrist denervation through an incision over the back of the left wrist (A), there is a hardly noticeable scar. Wrist function is almost the same for the left and right wrists in flexion (B) and extension (C).

The concept of partial wrist denervation can also be applied to other joints in the hand. The bone behind the thumb, is a wrist bone called the trapezium. When there is severe arthritis, as in Figure 3-6, the trapezium is usually removed, in order to relieve pain and improve function.



---

Figure 3-6. For severe arthritis of the wrist bone behind the thumb, called the trapezium, this bone is now usually completely removed and some form of spacer inserted. On the left x-ray, both the left and right trapezium have severe arthritis. In the right x-ray, note that the left trapezium (arrow) has been removed, and only a space remains on the x-ray.

---

In contrast consider Mindy’s complaint. “Doctor Dellon, I am a piano player. When I play, I get horrible pains in the base of my thumbs near my wrist. I have seen two famous hand surgeons, who, based upon my x-rays (Figure 3-7) they both said I should have my trapezium removed, or my thumb joint fused. Dr. Dellon, if the Hand Surgeon does that, I cannot play the piano. Can you help me?”

“Yes, Mindy, I can help you. Let me examine your thumb,” I said, and when I did examine her (Figure 3-7) I found that her pain was primarily in the front of the joint between the thumb and the trapezium.

“Mindy,” I said, “if I remove just the bone spur and remove the nerve to the joint, in each hand, your pain will be relieved, and you will play the piano again.”

Her result is noted in Figure 3-7, as she plays the piano.

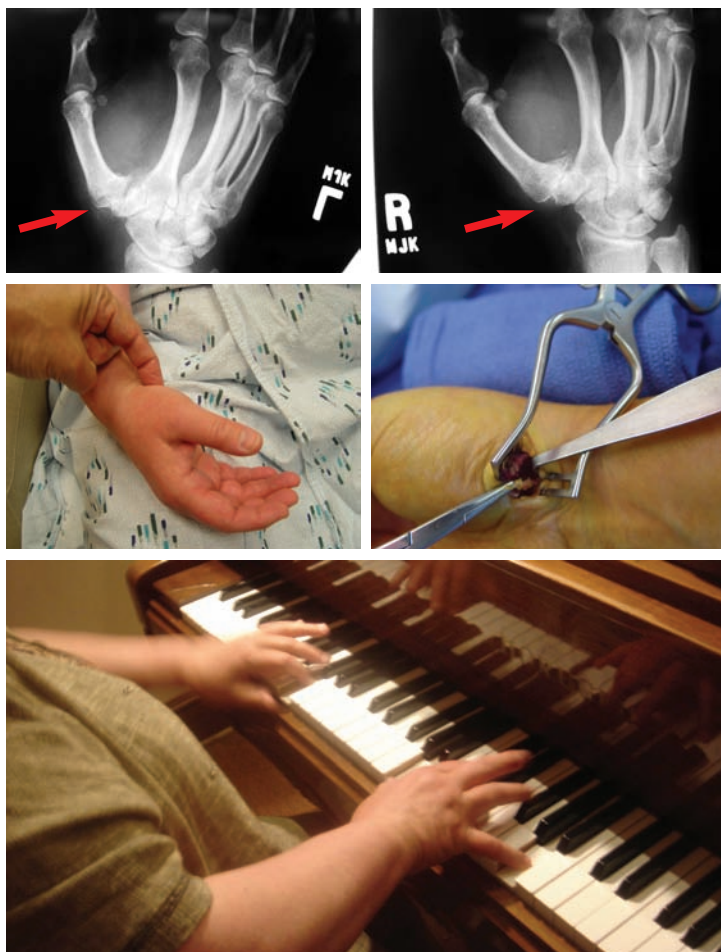

Figure 3-7. Top: X-rays of the left and right hand show severe trapezial arthritis. But examination of her hand (center left) demonstrated the pain to be only over a bone spur near the front, not the back, of the joint. Joint function could be preserved by removing the spur and denervating the thumb-trapezial joint. The intra-operative photo (center, right) demonstrates the spur removed (deep cavity) and the clamp holding the nerve to the joint. Bottom: After the same procedure on each hand, she is back playing piano.

## The Knee Joint: A Great Pyrenees

We too often take pain-free walking for granted. If we develop knee pain from athletic injuries, or an accident, or from arthritis, then each step becomes painful and our daily activities are impaired. We can become disabled. From arthritis, this occurs so often that Orthopedic surgeons now replace 300,000 knee joints each year. The operation is successful, remarkably, about 97% of the time. But for those without such improvement, their remaining pain becomes intolerable. This exact situation occurs within the United States about 9,000 times per year. For some patients, the knee replacement surgery is so painful afterwards, and remains so painful, that they will not consider having the other arthritic knee replaced. This situation is illustrated in Figure 3-8.

As a Plastic Surgeon and Hand Surgeon, it was a surprise to me when Orthopedic surgeons began to send to me patients with knee pain. To my amazement, there were no nerves to the knee joint demonstrated in any anatomy book. The only nerve that was illustrated was a nerve to the skin that is located just below the knee cap (the infrapatellar branch of the saphenous nerve). This nerve clearly was in line to be cut by every long incision used in Orthopedic surgery in the front of the knee, and so that nerve was clearly not the problem. An example of this nerve, injured by an arthroscopic procedure in a teenage soccer player is given in Figure 3-9.

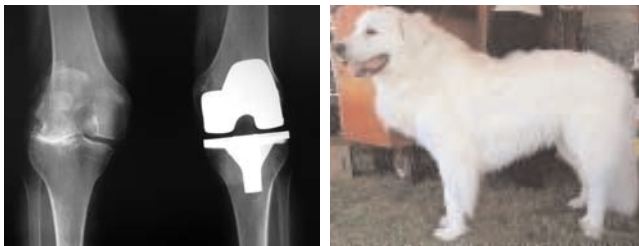

Figure 3-8. Left: Osteoarthritis is noted to be severe in the right knee. The left knee already has had a total knee arthroplasty, a knee joint replacement. When such a knee joint replacement still results in a painful knee, the patient just wishes to have a “Great Pyrenees.” A Great Pyrenees dog is noted at right.

Patients who have a knee joint replaced and still have knee pain are a very unhappy group of patients. They have had a big operation. Usually they have had several operations before the knee replacement and yet still have pain. Rehabilitation was painful and are on narcotics and antidepressants (Figure 3-10).

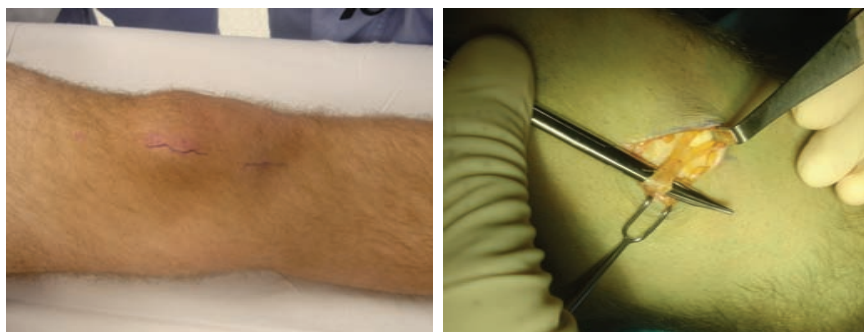

Figure 3-9. The known nerve to the skin below the knee cap (patella) is the infrapatellar branch of the saphenous nerve. Left: Ink marks an incision at the side of the patellar, and an arthroscopy portal (where the endoscope was put into the knee joint) below the patellar. The site below the patellar was painful. Right: At surgery, the infrapatellar branch is found and removed, leaving an area of numbness in place of the painful neuroma on the skin nerve.

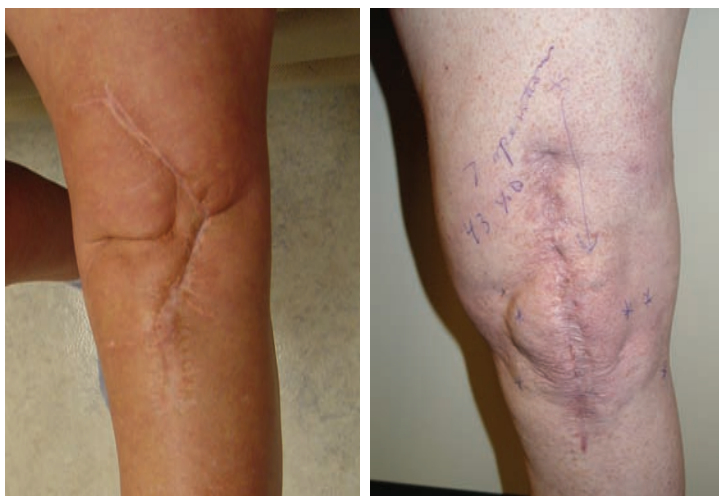

Figure 3-10. Examples of patients who still have pain after 18 (left) and 7 (right) previous knee operations. Each has had a total knee replacement and still has knee pain.

Removing the infrapatellar branch does NOT relieve knee *joint* pain.  
Therefore, in 1993, I began my research into the nerves to the knee joint.

---

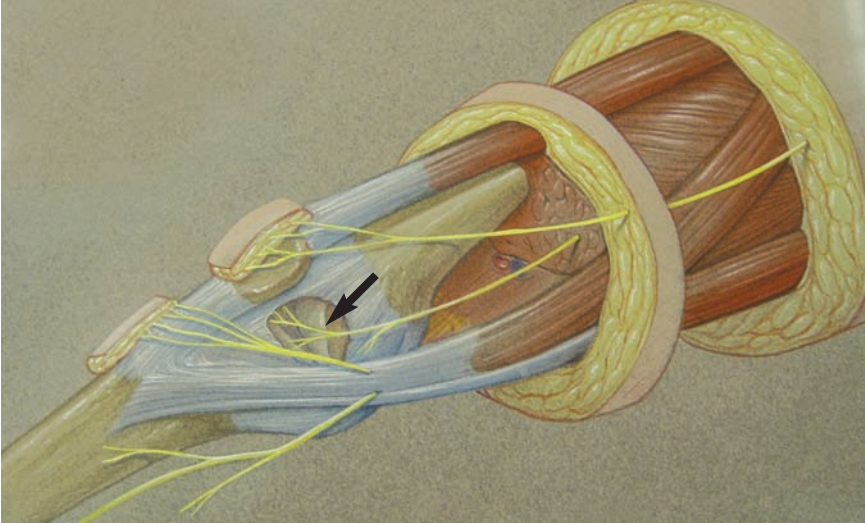


Figure 3-11A. Innervation of the human right knee joint. The medial (inside) view. Nerves to the skin and nerves to the knee joint are shown. Arrow points to the nerve to the medial aspect of the knee joint. This nerve is one of the main sources of medial knee joint pain.



This was published in 1994 (see reference in Figure 3-1, and Figure 3-11A and Figure 3-11B).

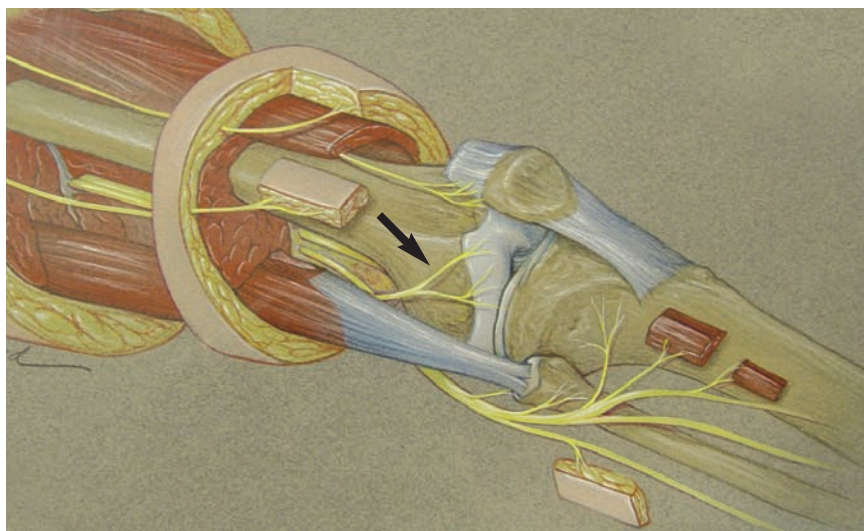


Figure 3-11B. Innervation of the human right knee joint. The lateral (outside) view. Nerves to the skin and nerves to the knee joint are shown. Arrow points to the nerve to the lateral aspect of the knee joint. This nerve is one of the main sources of lateral knee pain.

# Diagnosis of a Knee-Roma

The same approach used to develop my operations for partial wrist denervation was now applied to the knee joint. First, the nerves were identified through dissection of human cadavers, illustrated in Figure 3-11. Then patients who had a total knee replacement were evaluated with nerve blocks. Each patient must be at least 6 months after their knee replacement. If the patient had decrease in pain and could kneel and climb steps without pain after the nerve blocks, the presence of a neuroma of the nerve(s) to the knee joint was considered to be proven. At this point, the patient becomes a candidate for partial knee denervation surgery.

The relief of pain from partial knee denervation for patients who have had their knee replaced was so successful, it was incorporated into the leading book on knee surgery (Figure 3-13). [This chapter contains the results of 344 patients with 90% good to excellent relief of knee pain.](#) In most patients the nerve to the inside and the outside of the knee joint must be removed in addition to the infrapatellar branch of the saphenous nerve.

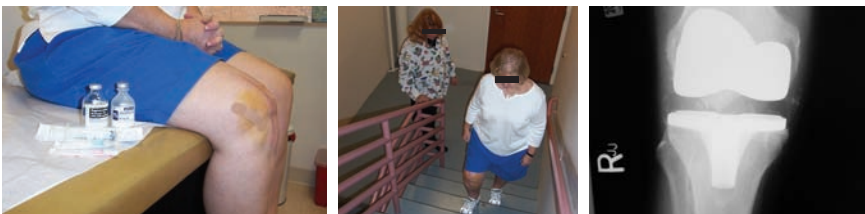

Figure 3-12. Nerve blocks are used to demonstrate that a nerve to the knee joint is the source of persistent pain after total knee replacement. Left: The anesthetics used for the block of just the nerves, not the knee joint. Center: Patient can climb stairs without pain [after the nerve block, demonstrating improved function when the painful nerve is blocked.](#) The patient is therefore an ideal candidate for a partial knee denervation procedure. Right: Demonstrates the excellent alignment of her knee replacement.

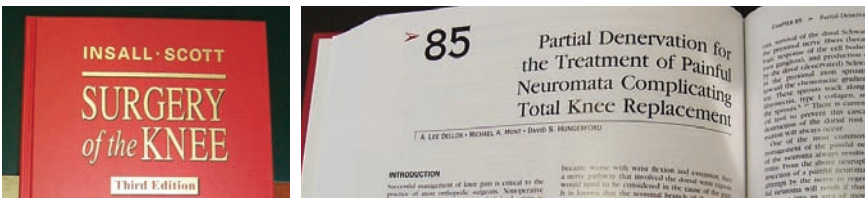


Figure 3-13. This 2000 edition of *Knee Surgery* contains Dellon's approach to partial knee denervation, and includes his first 344 patients that had this procedure done.



The surgery takes about an hour and a half. The surgery is done as an outpatient procedure. The patient walks immediately after the surgery, and usually knows the next day that the knee pain is finally gone. No rehabilitation is required. About one in twenty patients will need a second operation to remove a remaining painful nerve that was not detected at first.

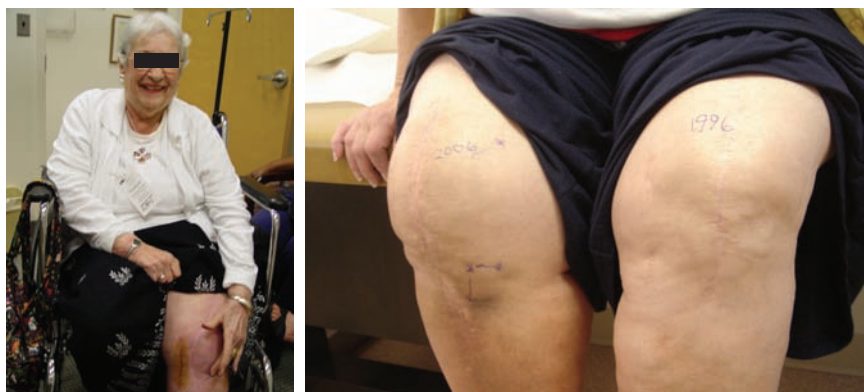

Figure 3-14. Examples of success after partial knee denervation in patients who have had pain. Left: This 82 year old woman has had 9 previous knee surgeries but still had disabling pain, essentially unable to walk. Here she is shown two weeks after her partial knee denervation procedure, smiling and ready to begin walking again. Right: A woman who had her left knee replaced in 1995, and had one of my first knee denervation procedures in 1996. Here she is seen in 2006, for her ten year follow-up. She came back because she now needs a partial knee denervation in her opposite leg which had a knee replacement one year ago.

---

At surgery, a small incision is made at each side of the knee, and the nerve to the joint, shown in Figure 11-10. A tourniquet is used so there is no bleeding, unlike the knee joint replacement procedure. Microsurgery is used to find the small nerves before they enter the scar around the knee implant. The knee implant is not exposed. After surgery, you know immediately that the knee joint pain is relieved. You walk immediately after the surgery. If the nerve to the skin has to be removed too, it is. This may make the skin more sensitive for a few weeks, and if this occurs walking in a heated swimming pool is then recommended. Otherwise there is no rehabilitation.

## Knee Pain in the Athlete

Once I had proven that knee pain after knee joint replacement was due to nerves that innervated the knee joint, and that I could treat this knee pain by removing these nerves, then my challenge was to relieve knee pain in athletes. I assumed that these same small nerves would be torn in the injuries that tore the ligaments of the knee, and that removing these nerves would help also these young athletes.

Relief of knee pain with a local anesthetic block means that removing that nerve will relieve that pain; a successful block implies a 90% chance of success with knee joint denervation surgery.

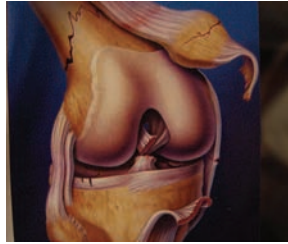

Figure 3-15. In the injured athlete, fractures to the knee cap (patella) or the bones about the knee, or rupture of the ligaments require musculoskeletal approaches to restore structural stability. **But when this stability is restored, and there is still knee pain, the doctor must consider that this pain is coming from an injured nerve to the knee joint.** (Image from a cover of the journal *Orthopedics*, in 2006.)

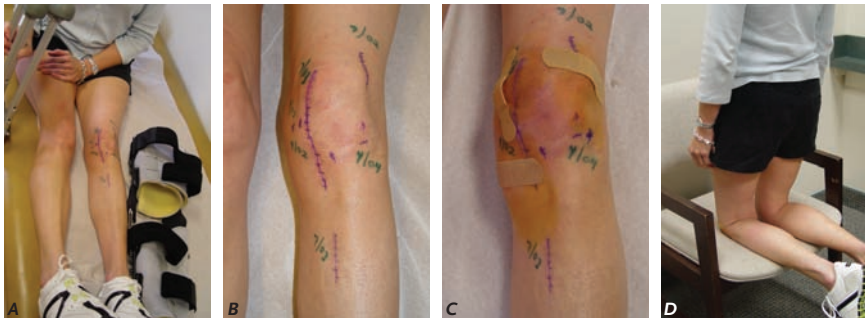


Figure 3-16. A young woman athlete is shown is A), disabled. Note her crutches and all her knee braces. B) Note the dates of each of the six surgeries she had within a two year time frame to treat her knee pain. C) Each band-aid is located at a site a nerve block. D) She has excellent relief of her knee pain, can climb steps and kneel down after the blocks, demonstrating that the remaining knee pain is due to small nerves torn in the injury.

The most common situation is to have a knee injury. Then to have an x-ray examination including an MRI. If a ligament is torn, it clearly needs to be reconstructed. If the MRI is normal and pain persists, or if the pain persists after the ligament is reconstructed, then pain due to a nerve injury must be considered. Knee pain of neurologic origin can be helped.

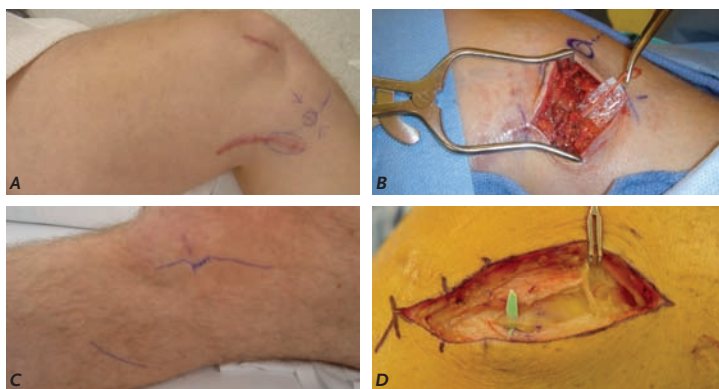


Figure 3-17. Two examples of male athletes with knee pain due to nerve injury. In A), this speed skater had had 8 years of knee pain. Shown is the site of his pain on the inside (medial) of the knee joint, where there is a scar from previous knee joint reconstruction. Neuroma pain site is marked by the circle and arrows. In B), a neuroma, held in the clamp in relationship to his site of pain at the medial knee. This nerve was removed and its end implanted into a nearby muscle. In C) a soccer player had lateral (outside) knee pain. The scar from the previous surgery on the joint is noted in blue. D) In surgery, the nerve injured and stuck in the scar is shown in relationship to the green marker. This nerve had to be removed, and it was allowed to drop back behind the gate.



Figure 3-18. Ten years ago, this woman, then a younger athlete, suffered severe knee pain due to sports injuries. She had several musculoskeletal operations that restored strength and stability, but did not relieve her knee pain. [Knee denervation surgery by Doctor Dellon returned her to a life where she can enjoy all the activity she still desires.](#) Here she kneels, smiling, demonstrating her knee pain relief.

## The Elbow Joint: Tennis Elbow and Golfer's Elbow

**Tennis Elbow pain is on the outside of the elbow.** Typically, the extension of the wrist required for the backswing puts a strain on the origin of the muscles on this (lateral) side of the elbow. The medical name for this is *lateral humeral epicondylitis*,



Figure 3-19. Like the mirror image twins pictured on either side of this young male professional lacrosse goalie, **tennis elbow and golfer's elbow pain** are quite similar, but, on opposite sides of the elbow their pain is transmitted by two different nerves. A future lawyer, seated on the far left, celebrates with the others that **there is now a chance to treat elbow pain by treating the appropriate nerve that transmits the pain message to the brain.**

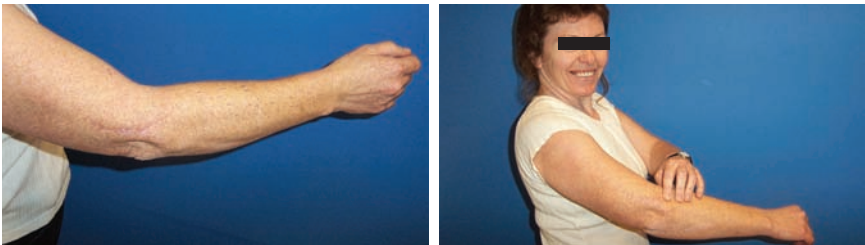

Figure 3-20. At two years after denervation of the right painful persistent tennis elbow, (left) the original painful tennis elbow scar is seen. Correction of that painful scar neuroma left the numb area noted by blue lines. Right: She smiles as she touches the previously painful area and extends her wrist now without tennis elbow pain.

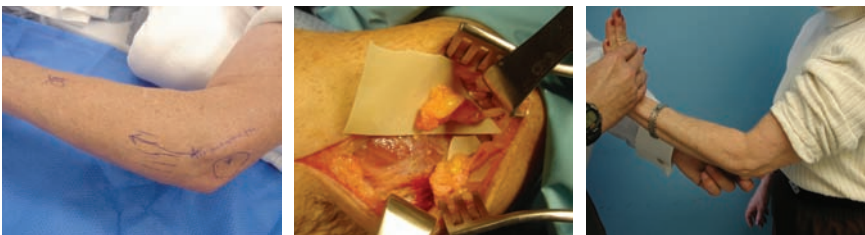


Figure 3-21. A woman who had previous surgery for her **painful tennis elbow**. Current pain site is noted by \*, dashed blue line is the first surgical site scar. Dashed area is already numb due to nerve injury during previous surgery. Center: In surgery, the previously damaged nerves to skin and tennis elbow are shown on yellow background material prior to their removal. Right: **Two years after Dr. Dellon's denervation surgery, she can extend wrist against resistance demonstrating relief of pain.**

suggesting that inflammation from torn origins of the muscles from the elbow are the source of pain. While most people recover from Tennis Elbow with heat, anti-inflammatory medications, steroid injections, splinting and rest, about 10% do not. There are several Orthopedic surgical approaches for this problem which release the tendons, remove the inflamed tissue, and sometimes drill holes in the bone or even remove a piece of the bone. These approaches may fail to relieve pain, or the surgical approach may, itself injure a nerve to the skin on that side of the elbow. Alternatively, it is possible to remove the small nerves that carry the pain message from the covering of the lateral humeral epicondyle, the bone from which these muscles arise, and thereby stop the pain message to the brain.

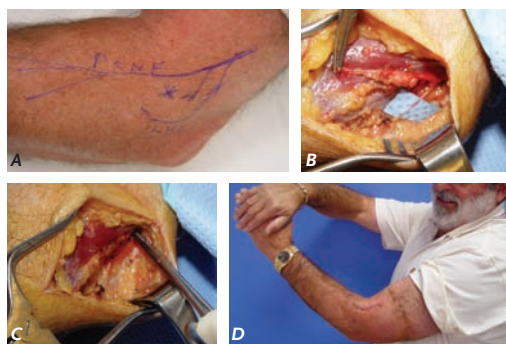


Figure 3-22. A man with disabling tennis elbow pain who has had no previous surgery. A: Before surgery, the \* notes the site of his pain. The other lines are the proposed location of the nerves to the site of the pain, the lateral humeral epicondyle (LHE) and the nerve to the skin, the posterior cutaneous nerve of the forearm (PCNF). In B, in surgery, the nerve to the LHE is seen on the blue background material, and the PCNF is held in the clamp. These two nerves join to become one nerve, which is then, in C turned and implanted into the triceps muscle to prevent them from growing back and causing pain again. D: Just one day after surgery, he smiles as his pain is gone and he can extend his wrist against resistance without pain. He will be able to use his hand immediately and by three weeks do as he wishes with his hand and elbow. Typically, no rehabilitation is required.

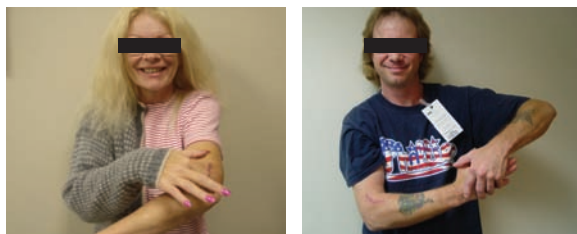

Figure 3-23. More people relieved of tennis elbow pain by denervation surgery.

Golfer's Elbow or Throwers Elbow are both conditions in which the same pain discussed above for Tennis Elbow occurs on the inside of the elbow.

This pain is caused when the wrist is pulled or flexed, instead of extended. This condition is common in baseball pitchers. Again, the problem is most often successfully treated without surgery, but, again, there are Orthopedic surgical procedures that alter the origin of the muscles that arise from the medial humeral epicondyle (MHE), the inside of the elbow bone. The good news is that in 2006, Doctor Dellon published a paper related to the nerve that carries the pain message from this bone and its muscles.\* The nerve had not been described before.

The really good news is that now this medial elbow pain can be relieved by removing this nerve. In addition to sports injuries, the medial elbow pain

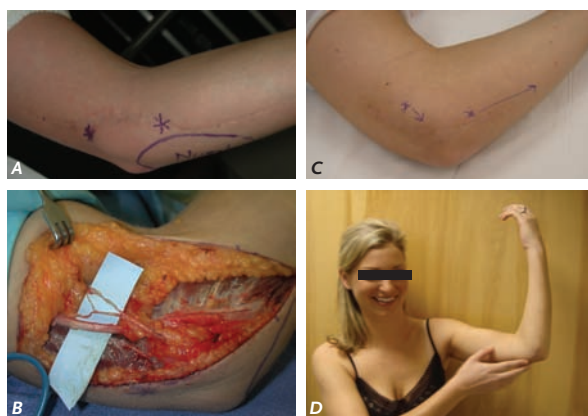

Figure 3-24. Two patients who have had previous surgery for ulnar nerve entrapment at the elbow, which is called **cubital tunnel syndrome** and who still have not only ulnar nerve entrapment but also **elbow pain**. In A, note the long incision from the first ulnar nerve transposition surgery. The two \* indicates the site of the bone pain at the elbow and the site of the painful neuroma to the skin. B: In surgery, the small nerves to the elbow are noted, and will be removed. (Photos courtesy of Chistopher T.Maloney, Jr., MD, Tucson, Dellon Institute for Peripheral Nerve Surgery). In C the previous incision is noted from the earlier two ulnar nerve surgeries. Again the two \* indicates the site of the bone pain at the elbow and the site of the painful neuroma to the skin. In D the patient is shown three months after the nerves have been removed. **She can touch the previously painful area now without pain, evidenced by her smile.**

\*Dellon AL, Ducic I, DeJesus RA: Innervation of the Medial Humeral Epicondyle: Implications for Medial Epicondylar Pain, J Hand Surg, 31B:331-333, 2006.



can be a complication of elbow surgery to decompress the ulnar nerve. This nerve becomes compressed in the *cubital tunnel*. Surgery to decompress the ulnar nerve in the cubital tunnel can create a neuroma of the nerve to the skin and the nerve to the bone. **If a patient has pain when the ulnar nerve surgery scar is touched** and the pain goes to the little finger, the ulnar nerve is still compressed. If the pain goes to the elbow or forearm skin, there is a neuroma of the medial antebrachial cutaneous nerve. But if the **pain is felt to be in the elbow itself, then the same nerve that causes the pain of Golfer's elbow and thrower's elbow is the source of this elbow pain.**

Elbow pain, that is not due to bone fragments in the joint, is most likely due to injury to the nerves to the elbow joint. These painful nerves can be removed. Partial elbow denervation offers hope for elbow pain.

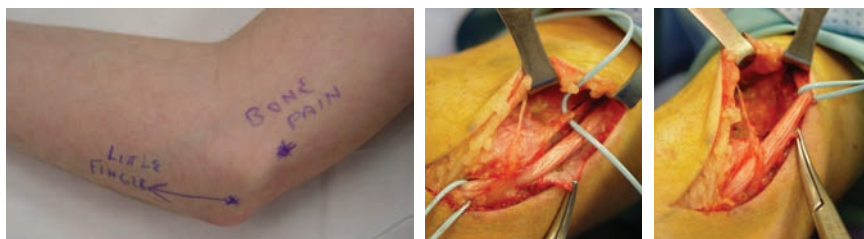

Figure 3-25. Twelve year old girl who injured her right elbow falling during soccer. There were no fractures but she had persistent elbow pain and numbness in her little and ring fingers. Left: One year after her fall she had both bone pain localized at the \* and evidence of ulnar nerve compression in the cubital tunnel. Center: In surgery, the compressed ulnar nerve is encircled with a blue rubber band, while the nerve to the medial humeral epicondyle lies over the loose blue rubber band. This is the nerve that also causes Golfer's and Thrower's Elbow pain. Right: This nerve has been removed and its end placed into the triceps muscle in the dark tunnel beneath the retractors.

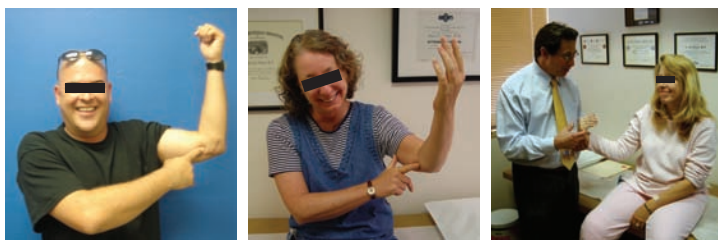

Figure 3-26. Three more patients who have had relief of their medial elbow pain by denervation of the medial humeral epicondyle. In the right example, the woman can flex her wrist against resistance, which is the movement that causes Golfer's Elbow pain.

## Shoulder Joint: Bursa, Rotator Cuff, or Nerve?

Do you have shoulder pain? Did you injure and tear your rotator cuff? Did you have your rotator cuff repaired and still have shoulder pain? **PERSISTENT**

**SHOULDER PAIN CONTINUES IN 20% OF PEOPLE AFTER ROTATOR CUFF REPAIR!**

Do you have shoulder pain? Did you have arthritis in your shoulder due to aging, an old fracture, or subacromial bursitis? **PERSISTENT SHOULDER**



Figure 3-27. Doctor Oskar Aszmann, in 1995, when he was doing the basic anatomy dissections with me to demonstrate the existence and pattern of the nerves to the shoulder joint. This research was critical to my approach to shoulder denervation to relieve joint pain. Note the microsurgical dissecting tools he is using. He is now Associate Professor of Plastic Surgery at the University of Vienna, in Austria, and a leading nerve researcher.

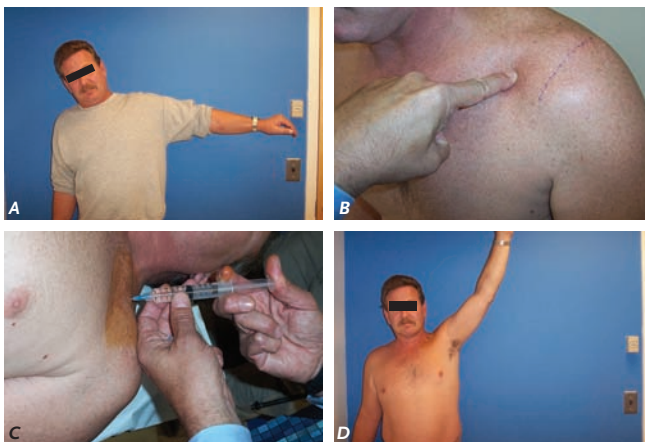


Figure 3-28. A: This man has had a rotator cuff repair but still has left shoulder pain and cannot lift the left arm higher than shown here without pain. Note position of white box on the blue wall as a marker of this height. B: First step is to prove that the shoulder pain is coming from a nerve. This is done with a local anesthetic as shown in C. D: **Fifteen minutes after the block, his pain is gone, and he can lift his left arm.** Note position of the white box as a marker. This means that he should get a great response from a left partial shoulder denervation. Just the nerve to the front of the joint is removed at surgery.



PAIN CONTINUES IN 20% OF PEOPLE AFTER SUBACROMIAL PLASTY, the operation for shoulder joint inflammation.

Do you have shoulder pain? Have you had to have your shoulder joint replaced due to arthritis after a fracture, or rheumatoid arthritis?

Well, PERSISTENT SHOULDER PAIN EVEN CAN CONTINUE AFTER A SHOULDER JOINT REPLACEMENT.

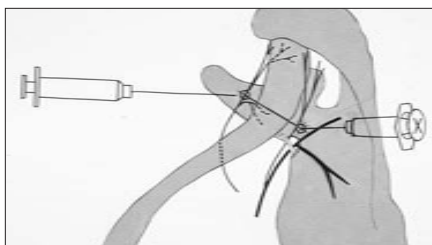


Figure 3-29. This figure shows the approach for the nerve block to the front of the shoulder joint of the nerve identified through our anatomic research. The nerve is a sensory branch from the motor nerve to the pectoralis muscle.

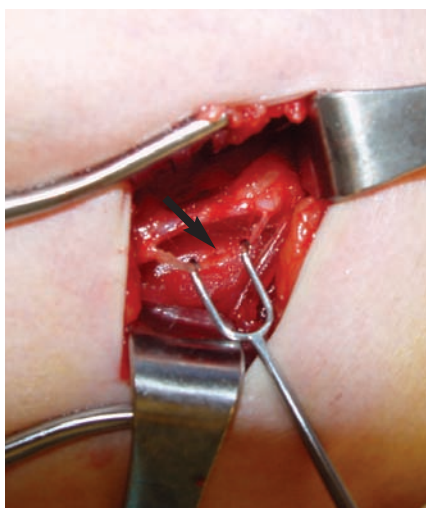
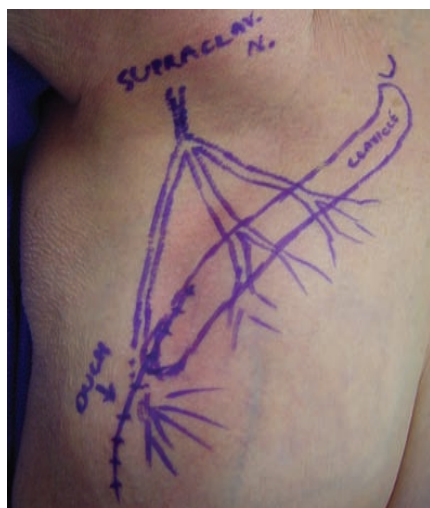


Figure 3-30. Left: The surgery. With the patient under general anesthesia, a drawing was made to show the collar bone (clavicle). The blue hatched line is the scar from previous orthopedic shoulder surgery. The supraclavicular nerve is shown (arrow). This nerve is only for the skin sensation and does not give shoulder pain. Care is taken to save this nerve when only a shoulder denervation is done. Right: A small incision is made below the clavicle, near the shoulder, the pectoralis muscle is spread apart, and the small nerve to the shoulder capsule is identified. This nerve is then removed to relieve the shoulder pain.

The surgery is done with the patient asleep under general anesthesia. An incision is made below the collar bone, the chest muscle (pectoralis) is spread apart to find the small nerve to the front of the shoulder joint. This nerve is removed. You can move your arm and use your hand immediately after the operation. This shoulder denervation assumes that the Orthopedic surgery has reconstructed the shoulder ligaments and the muscles have sufficient strength, and that there are no scars limited joint mobility. Then you can raise your arm immediately following the surgery.

---

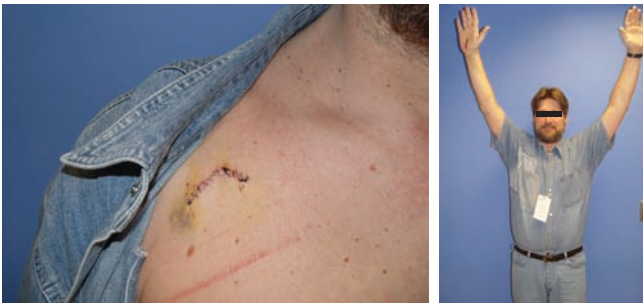

Figure 3-31. **Immediately following the shoulder denervation, you can begin to use your shoulder.** Left: The scar for the shoulder denervation is shown 5 days after the surgery. Right: On that same day, the right shoulder can be raised as high as the left without pain. Shoulder denervation surgery assumes that shoulder joint itself is strong and that the shoulder pain is coming from the nerve, which was injured originally.

---

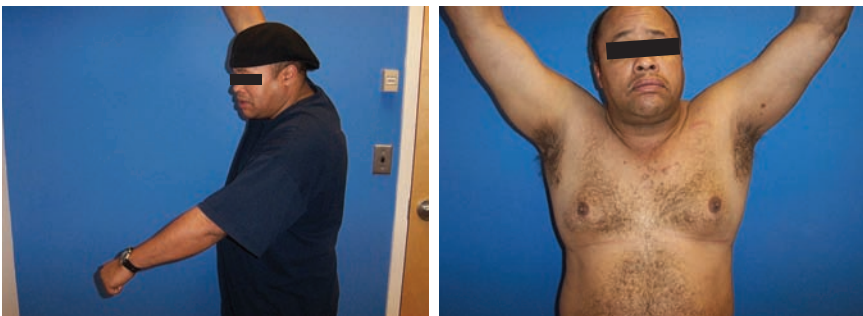

Figure 3-32. **This man had two shoulder arthroscopies but remained with pain.** Left: Note the left arm could not be lifted more than this without shoulder pain. After the nerve block he had less pain and improved his shoulder range of motion. This meant that he would be a good candidate for shoulder denervation. Right: **One month after surgery, he can lift his left shoulder without pain.**

---

When the skin is hypersensitive or painful in addition to the shoulder joint being painful, then the supraclavicular nerve branch to the original shoulder surgery scar can be removed. This nerve is found at the shoulder, traced into the neck, where it originated, and removed. This leaves numbness in the previously painful shoulder skin area, but the skin pain is gone. An example of this type of surgery is illustrated in Figure 3-33.

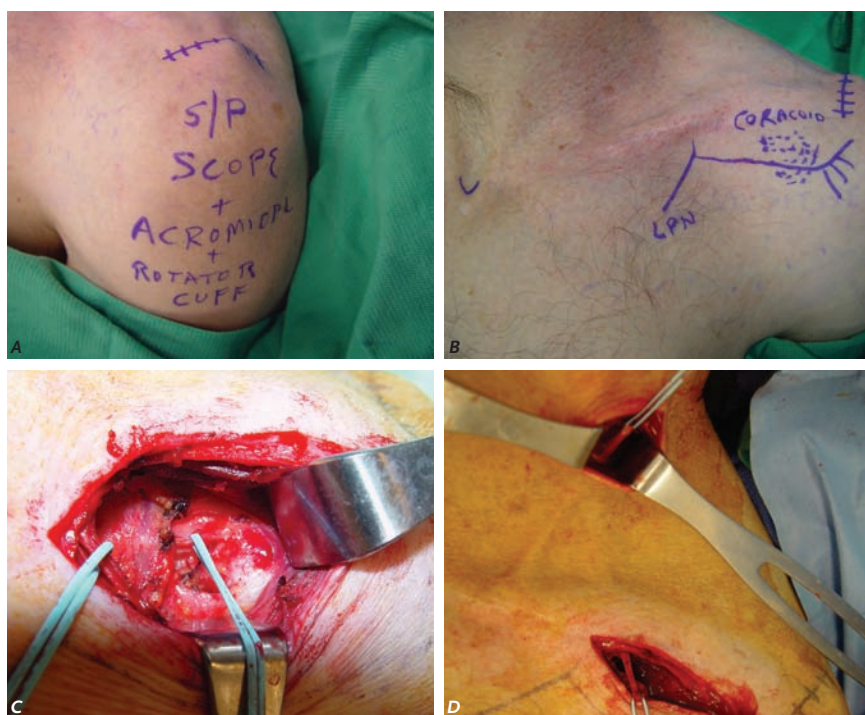


Figure 3-33. The patient has already had, as noted in A, a shoulder arthroscopy, an acromioplasty and a rotator cuff repair but **still has disabling shoulder pain**, and has hypersensitive skin. B: the front view indicates the location of the nerve to the pectoralis muscle, the lateral pectoral nerve (LPN), whose motor function is preserved, and the branch that we remove going towards the shoulder joint. This branch crosses the bone called the coracoid, which is why the nerve block is done in that location. In surgery, C the two blue rubber bands are each around a nerve. The larger nerve to the left is the one that goes to the painful skin, and arises in the neck, and the smaller one goes to the shoulder joint and will be removed first. D: The nerve to the skin is shown in the incision near the shoulder, and its origin in the neck is not shown. This nerve will be removed too, so that instead of painful shoulder skin, there will be an area of numbness. **After this surgery, both the skin pain and the shoulder joint pain will be gone.**

# Shoulder Joint Replacement Surgery

If shoulder pain persists even after replacement of the shoulder joint, a consideration should be that the pain is coming from a nerve to the

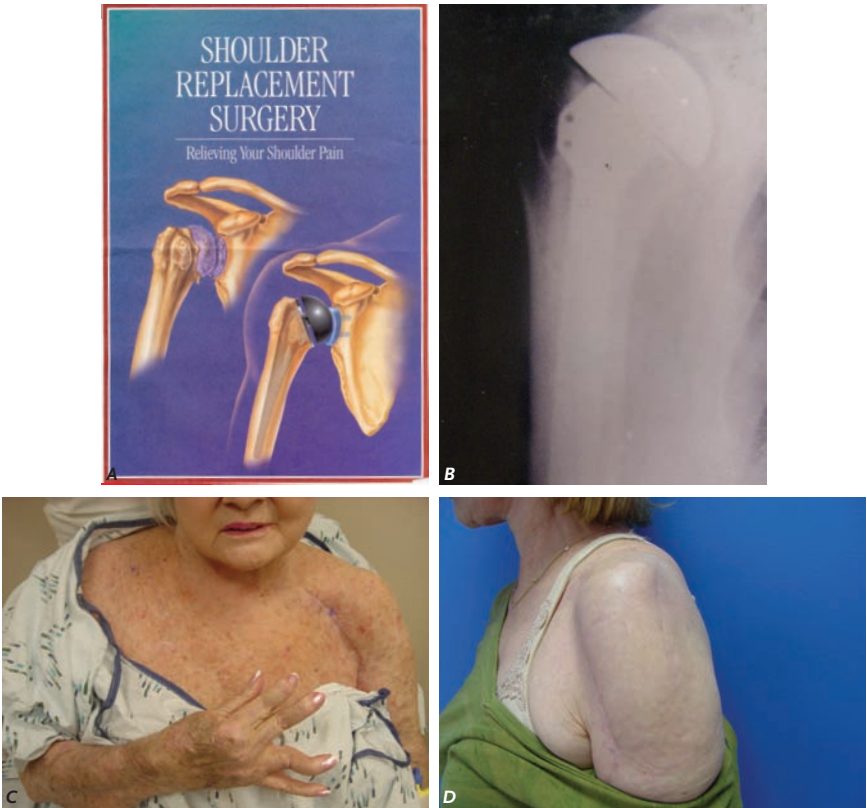

Figure 3-34. A: Cover of the journal Orthopedics featured shoulder joint replacement. B: An x-ray of a new shoulder joint in place. C and D: Patients whose shoulder joints have been replaced, but they still have shoulder pain. The \* on the woman's shoulder in C) shows the site of persistent pain. This can be helped by the shoulder denervation surgery.

shoulder joint that is stuck in scar around the new shoulder joint implant. If that is true, then there is hope that the pain can be relieved by a joint denervation.

---




Figure 3-35. I received this card in 1997. It was from one of my first partial shoulder joint denervation patients. The card reads, "Dear Dr. Dellon, There are just no words to adequately express our thanks and gratitude to you. To receive a hug from Debbie with both her arms after almost 7 years was the best feeling in the world."

---

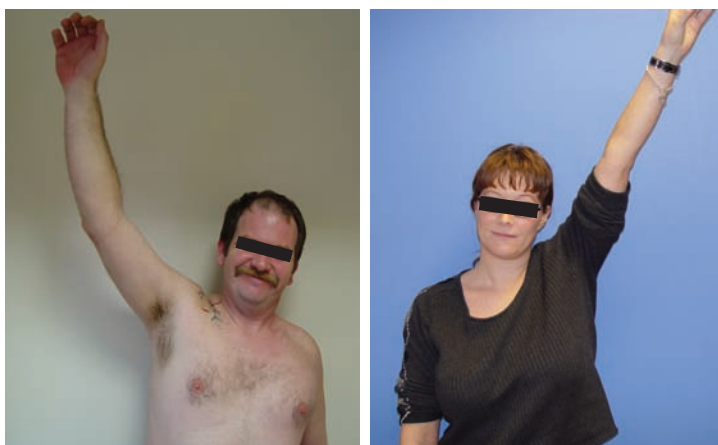


Figure 3-36. Patients wave good by to us as we leave the shoulder denervation section of this chapter. Each of them is waving to us with a hand that could not be lifted above the shoulder level due to shoulder pain. Each has had a shoulder joint partial denervation procedure.

---



## The Ankle Joint

If you have ever sprained your ankle, you know **the intense immediate excruciating pain you feel as the ligaments that hold the ankle bones together rips apart**. With ice, anti-inflammatory medication, and some form of a splint, pain usually subsides quickly. Immobilization, keeping the bones and ligaments from moving, helps healing, but it also **stops the nerves within the ligaments of the ankle joint to stop sending pain signals**.

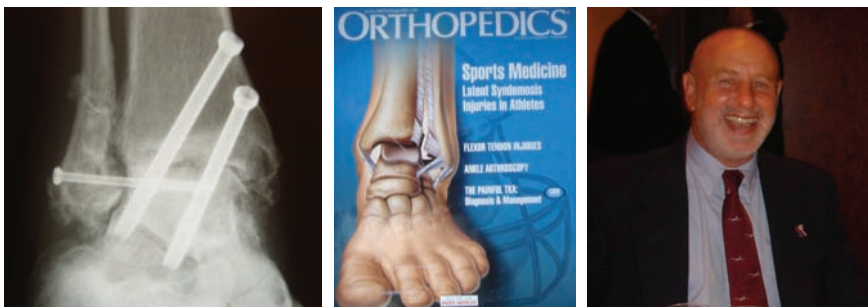

Figure 3-37. Left: “Screwed” fixing a fractured ankle. Center: Torn ligaments on journal cover; no nerves are illustrated. Right: Why is this man smiling? He knows pain can be relieved by getting rid of something. **“It is OK to lose your nerve. Lose it and use it” he says.**

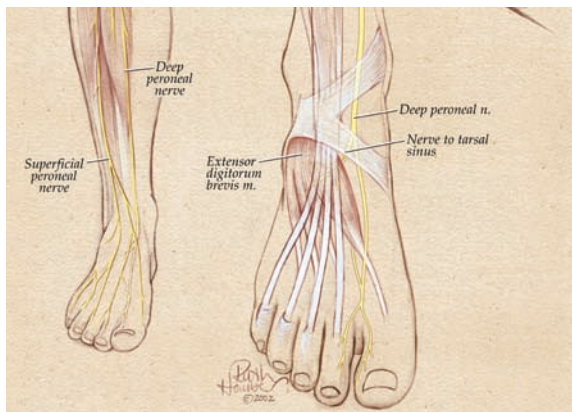


Figure 3-38. The nerves to the skin around the lateral ankle joint are the superficial peroneal nerve shown in yellow, and the sural nerve, not shown, behind the lateral ankle bone. The deep peroneal nerve, yellow, crosses the top of the ankle and sends branches to the sinus tarsi region. This illustration is from the Dellon.com website.

“Wait, what did you say? There are nerves sending pain signals from the ankle joint?” a shrill voice from medical knowledge screams out. “No way. The anatomy books do not show any nerves to the ankle joint,” the hysterical, historical voice concludes its objections.

Really good news! There are nerves to the ankle joint. These nerves can be blocked with local anesthetic. If pain is relieved by a nerve block, these nerves can be removed and your pain can be relieved.

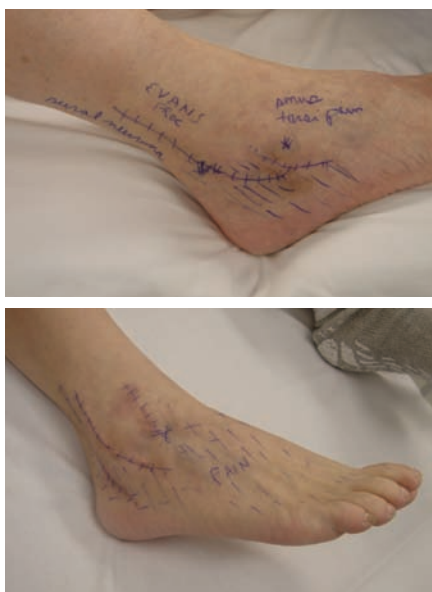

Figure 3-39. Two ankles that have required surgery for their fracture/dislocations. The surgical scars are outlined with blue hatched lines. Areas of painful skin are shown outlined by the blue ink dashes. Top: The location of the **disabling sinus tarsi pain** is shown by the \* and the words “sinus tarsi.” The second \* is located over the words “sural neuroma” and is the site where the sural nerve was injured and stuck in the surgical approach for the Evans procedure, a procedure used to tighten the loose lateral ankle ligaments. Bottom: There have been three operations already on this painful ankle. The \* is located over the sinus tarsi. The blue ink dashes indicate painful skin due to both the sural nerve and the superficial peroneal nerve. The good news is that even with this much previous surgery and long lasting pain, the nerve to the sinus tarsi, the deep peroneal nerve, can be removed, relieving the ankle joint pain. The nerves to the skin, the sural nerve and the superficial peroneal nerves also can be removed, leaving the skin area numb. The end of the nerve is implanted in a muscle above the ankle, so that wearing a shoe no longer causes pain when the skin is touched.

When the fracture or dislocation or bad sprain occurs on the outside of the ankle, the most common place for it to occur, ligaments that surround a space called the *Sinus Tarsi* get torn. In the approach to correct the fracture and the ligaments, the Foot and Ankle surgeon may need to tighten or reconstruct the ligaments in addition to corrected the fractures. This creates the possibility for lateral ankle pain to be due to injuries (neuromas) of the nerves to the skin as well as nerves to the joints. Both sources of nerve pain must be corrected to relieve pain on the lateral aspect of the ankle. In Chapter 1, the concepts related to removing the painful nerve and implanting it into a muscle were discussed and illustrated.

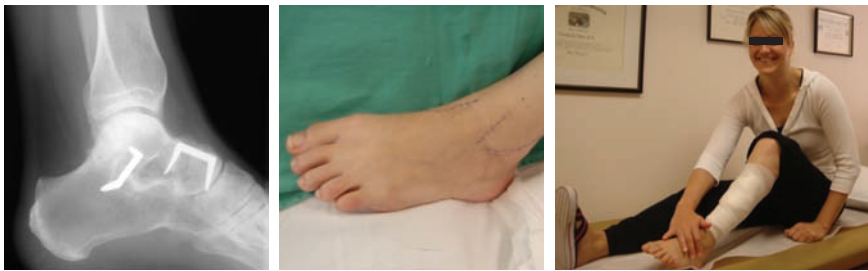

Figure 3-40. This 26 year old woman injured her left ankle 7 years ago. She has already had three ankle surgeries. The last one, shown (left) demonstrates the metal clips where she had had her ankle fused. *Her ankle still hurts despite its fusion.* Center: The previous surgical scars created painful skin that she would not even let the bed sheets touch. She uses a cane or crutches despite having an ankle fusion. Right: She is shown the day after her surgery. She had a denervation of her sinus tarsai (removal of the deep peroneal nerve) . She also had removal the superficial peroneal nerve to remove the source of pain to the skin. Note the smile on her face as she now can touch the skin and press on the sinus tarsi region without the previous pain. *Finally, she can walk without ankle pain.*



Figure 3-41. “Hair” today, Gone tomorrow. And so it can be for Nerve Pain. “Here” today, and Gone tomorrow. Partial Joint Denervation makes this possible. “It is OK to lose your nerve,” as long as the correct nerve is chosen to lose.



Here we focus on the pain in the lateral ankle joint, and the sinus tarsi region.

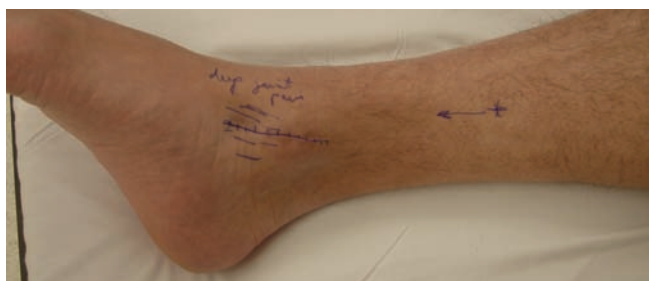

Figure 3-42. The **inside of the ankle, the medial ankle, can hurt too**. This man had a fracture of the ankle requiring an incision, hatched blue line, over the medial malleolus. He now has painful skin in this region and deep medial ankle pain. This type of pain can be due to the branches of the saphenous nerve. The \* is where tapping on **the saphenous nerve causes pain to go into the painful skin and the ankle**. A nerve block in this location will relieve the pain, permitting walking without ankle pain, and touching the numb skin.

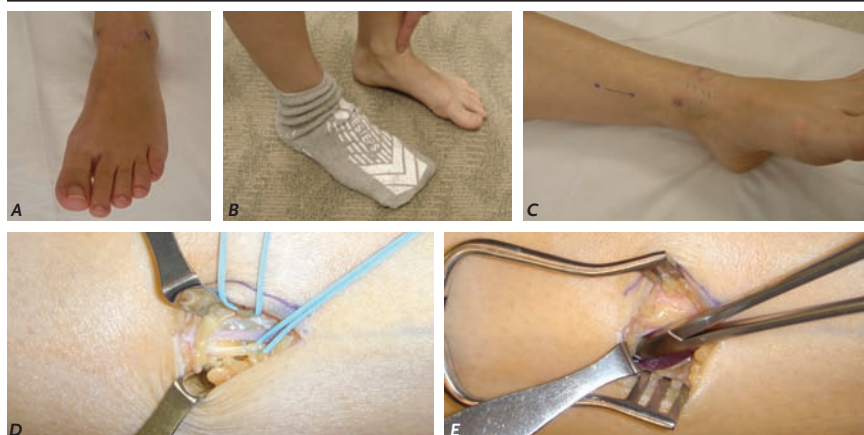


Figure 3-43. A marathon runner and triathlete injured her left ankle, and has had **disabling ankle pain for four years**. A: The two ink marks are the site of her first operation, and arthroscopic ankle surgery which left her with worse pain, both on the inside (medial) and outside (lateral) aspect of her ankle. The S-shaped scar across the front of her ankle is from a neurosurgical attempt to remove scar tissue from her superficial peroneal nerve. This did not help her either. B: She points to the site of her medial ankle pain. C: the \* indicates the site where a nerve block of the saphenous nerve relieved the medial ankle pain. The blue dash marks are where she has scar directly at the medial ankle arthroscope portal. D: The saphenous nerve branches are encircled by the blue rubber bands. The saphenous vein is noted between them. These two nerve branches are removed and, in E the nerve ends are implanted into the underlying muscle. Her functional results are demonstrated in Figure 3-44. **She has had great pain relief.**

There are many individual joints related to the ankle, and there are also joints between the ankle bones and the toes bones. It is critical to be sure there are no remaining bone fragments in these joints before doing the denervation procedures. As note above, in some patients, an injured nerve to the skin of the foot must also be removed to relieve the foot and ankle pain in addition to the partial ankle joint denervation procedures.

PRINCIPLES OF PARTIAL JOINT DENERVATION:

*There are nerves to the joints, these nerves can be the source of pain, these nerves can be removed, nerve blocks determine which nerves to remove.*

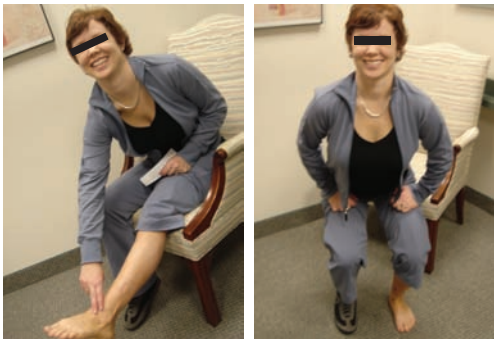

Figure 3-44. The marathon runner and triathlete, whose left ankle pain problem is shown in Figure 3-43, first had an operation to help the lateral side of her ankle, to treat her sinus tarsi pain problem. She touches the lateral aspect of her foot (left), where removal of the deep peroneal nerve helped her lateral ankle pain. That surgery was six months ago. Right. She is just one day after the surgery for her medial ankle pain. The saphenous nerve was removed, as described in Figure 3-43. Her she is shown squatting down with full ankle flexion without pain. “Doctor Dellon,” she said, “Before surgery I could not do squat without pain. Now I can squat without any pain. Thank you Doctor Dellon.”

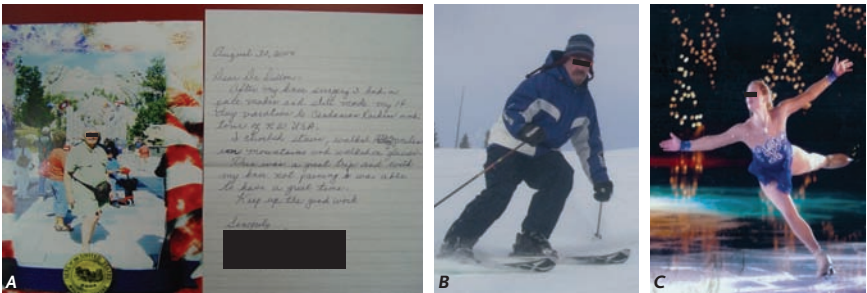


Figure 3-45. Improved function and enjoyment of life after partial joint denervation.  
A: After knee denervation, B and C after ankle denervation.

## Pain Solutions Summary

Joint pain must first be considered to be due to a problem related to the ligaments, bones, cartilage that make up the structure and function of a joint. However, it must never be forgotten that the pain experienced is transmitted from these structures to the brain by a peripheral nerve.

*When joint pain continues after all aspects of the musculoskeletal system have been treated, then the remaining source of joint pain must be considered to come from an injured nerve.*

Although traditional textbooks do not document the presence of nerves in joints, Doctor Dellon's research has documented the presence of nerves in joints. Surgeons trained in microneurosurgery can identify these nerves, and these nerves can be removed by appropriately designed surgical procedures. *The Dellon partial joint denervation procedure is demonstrated to be successful for the shoulder, elbow, wrist, knee, and ankle joints. Partial joint denervation can relieve pain and preserve joint function.*

There is hope for you.

Visit [Dellon.com](http://Dellon.com) or call +1 877-DELLON-1 (+1 877-335-5661).

